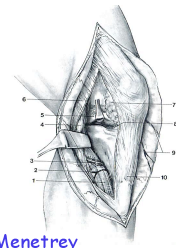



 3rd Advanced Course in
 Knee Surgery
 January 17th - 22nd 2010

Intra-articular proximal tibia fractures: Approaches

Jacques Menetrey
 Unité d'Orthopédie et Traumatologie du Sport (UOTS)
 Service de chirurgie orthopédique et traumatologie de l'appareil moteur
 University Hospital of Geneva,
 Geneva Switzerland

Strategy of treatment

- Diagnostic of injury
 - Radiographs, Ct-scanning, event MRI
- Skin and soft tissue injury
- Preoperative planning
- Equipment needed
- Installation

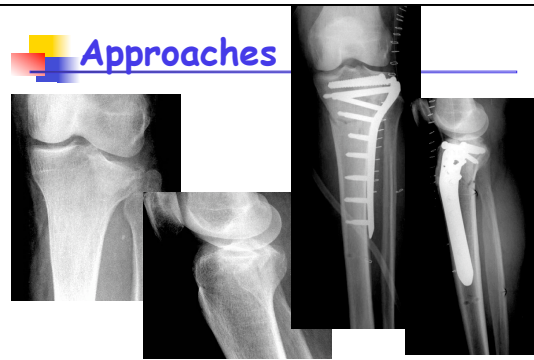
AO Manual of internal fixation

Approaches

- Approaches is determined by the planned treatment, and therefore the fracture personality

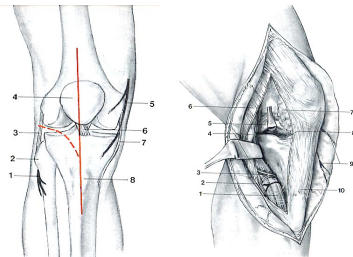
- Preservation !

Approaches

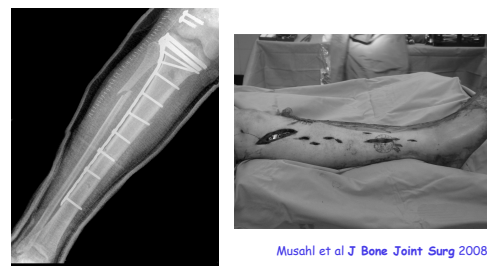

Approaches

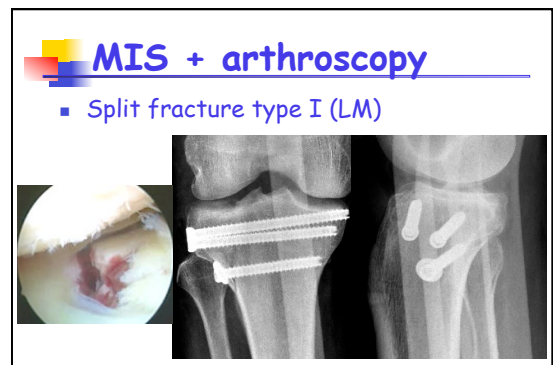
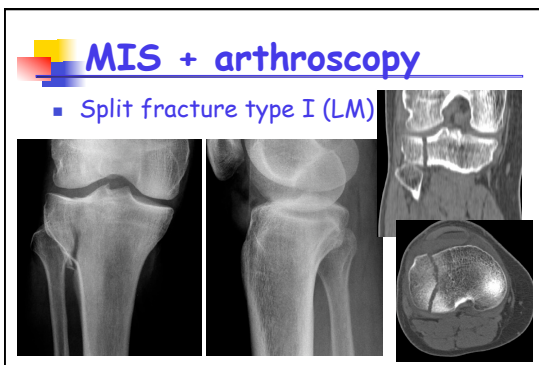
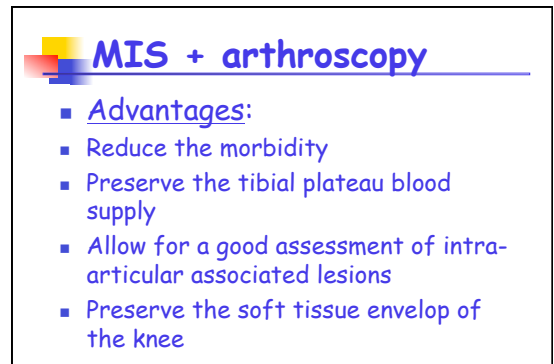
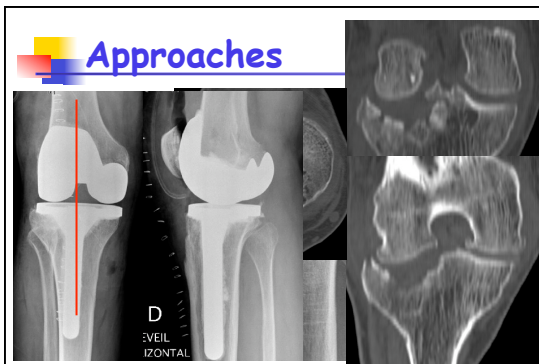
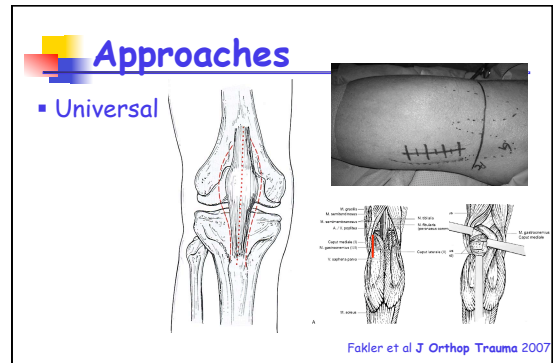
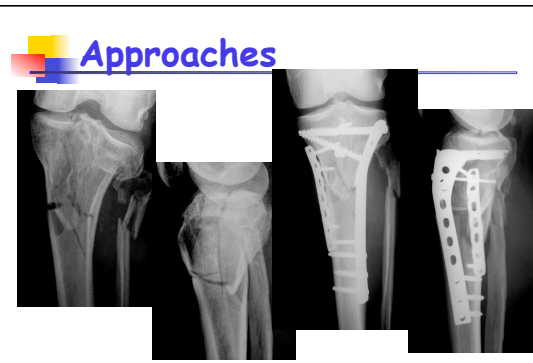
- Standard



MIS



Musahl et al J Bone Joint Surg 2008



MIS + arthroscopy

- Pure depression fracture type III

MIS + arthroscopy

- Pure depression fracture type III

MIS + arthroscopy

Approaches

36 y old male