

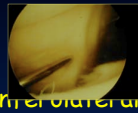
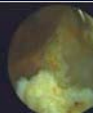

Arthroscopic Lateral Retinaculum Release for PF instability

François Kelberine


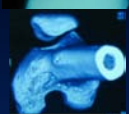

Aix en Provence - France



Technique

- ✓ Scope @ anteromedial portal = retractor
- ✓ Needles /landmarks  
- ✓ Electraucautery @ interportal
 - ✓ Small hole at the upper part
 - ✓ Subcutaneous tissue inflating
- ✓ (Cartilage flaps & LB resection) 

3 patterns

- ✓ Objective Instability 
- ✓ Potential Instability 
- ✓ Pseudo Instability (AKP) 



LLR & Patellar Dislocation

- ✓ Bigos & Mac Bride CORR 1984 : 100% stable @ 1 year
- ✓ Schonholtz Arthroscopy 1987 : 67% satisfied @ 4 years
but instability included and only 2/3 reviewed FU
- ✓ Dandy & Griffith JBJS 1989 : 41 dislocations, 68% no recurrence
- ✓ Aglietti CORR 1994 : 20 cases, 40% recurrence @ 8 years
- ✓ Dandy & Desai Arthroscopy 1994 : no decrease with time @ 8 years
- ✓ Panni & al Arthroscopy 2005 : @ 5 to 12 y 50% satisfied worse with time

LLR & Patellar Dislocation

- ✓ Woods AJSM 2006 : 20 cases, prospective study @ 2 years
No recurrence
IKDC : 45 to 76pts
Subjective satisfactory results (53 to 86pts) ++, 1/20 poor
 - ✓ Christoforakis Knee Surg Sports Traum Arthro 2005 : Cadaver study
Converse effect / force to dislocate laterally
Decrease > LRR
 - ✓ Merican J Biomech 2008 : Medial and lateral stability decrease with LLR
- Rate of recurrence unacceptable / detrimental injury & ADL
Age of population

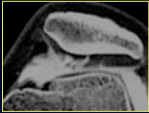
LLR & Patellar Dislocation

- Combined medial arthroscopic reconstruction  
- ✓ Chassaing J Trauma Sport 1992 : 29 cases with medial ST plasty
79% stable
 - ✓ Haspl Arthroscopy 2002 : Medial arthroscopic suture
 - ✓ Coons Arthroscopy 2006 53 cases with medial thermal shrinkage
86% stable @ 2 y
 - ✓ Ricchetti Arthroscopy 2007 FU > 2y 14 studies
medial reconstruction + LRR > LRR alone (P<0.001)

LRR & Instability / AKP


AKP & Cartilage

- ✓ No influence
Christensen CORR 1988
- ✓ Chondral damages detrimental
Schultz Sportverletz Sportschaden 1996
Panni Arthroscopy 2005
- ✓ Normal cartilage detrimental
Kelberine & SFA Ann SFA n°5 1996



Correction of Tilt or Subluxation

- ✓ Effective
 - ✓ Koskinen Acta Orthop Scan 1990
 - ✓ Kelberine & SFA Ann SFA n°5 1996
- ✓ Useless or pejorative
 - ✓ Kolowitch AJSM 1990
 - ✓ Vaatainen Arch Phys med Rehab 1994




LRR & Instability / AKP

The difference is in the predisposing factors (tilt, subluxation)

AKP alone

- ✓ Bigos & Mac Bride CORR 1984 : 71% @ 1 year
- ✓ Lankener AJSM 1986 : 64,7% satisfactory
- ✓ Schontholtz Arthroscopy 1987 : 15% @ 4 year
- ✓ Schultz Sportverletz Sportschaden 1996 : 83% @ 3 year



Instability alone


- ✓ Vaatainen Arch Phys med Rehab 1994 : 42 cases @ 4 year not effective

Anatomical correction without clinical improvement

LRR & Instability / AKP

Comparative studies / symptoms

- ✓ Christensen CORR 1988
 - ✓ AKP : 76% satisfactory results stable in time
 - ✓ Subluxation : results drop down from 76% to 30% @ 4 years
- ✓ Aglietti Arthroscopy 1989
 - ✓ AKP : 60% & Instability : 68%
- ✓ Kelberine & SFA Ann SFA n°5 1996 prospective study, 60% satisfied
- ✓ Fabbriciani Arthroscopy 1992, 50 cases @ 3 year
 - ✓ AKP : 71% & Instability : 76%
- ✓ Panni Arthroscopy 2005 : 100 cases from 5 to 12 years
 - ✓ AKP : 70% / (Instability : 50%)



Conclusions

Merchant & Mercer CORR 1974
Osborne & Fulford JBJS 1982



LRR spontaneous onset of AKP

- ✓ **CONTROVERSIAL**
- ✓ Reasonable initial step to treat FP functional instability
 - ✓ Young patient with failure of medical treatment
 - ✓ Avoid shaving (drop down to 28% of satisfying results)
- ✓ Doesn't burn any bridge
- ✓ Fithian & PF study group Arthroscopy 2004
 - ✓ LLR : 1 to 5 cases / year (experimentd surgeons in FP)
 - ✓ Objective evidence (radiological or clinical)
 - ✓ preoperative specific informed consent