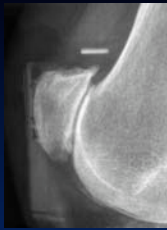



Place of arthroscopy in PF arthritis ??




François Kelberine
Aix en Provence - France



Treatment options

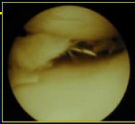

Donnel The Knee 2007

- ✓ Medical
- ✓ Operative conservative
 - ✓ Lateral release, excision of lateral spurs
 - ✓ Tibial tubercle osteotomy
 - ✓ Cartilage replacement
 - ✓ Patellectomy
- ✓ PF arthroplasty
 - ✓ PF uni
 - ✓ TKA



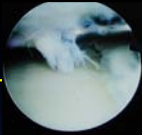
Pathoanatomy

- ✓ Remove locking cartilage flaps
- ✓ Decompression Dzioba Am J Sport Med 1990
- ✓ Remove lateral impingement
- ✓ Sensorial neural damage Mori Bull Hosp Jt Dis Orthop Ins 1991
Vega Arthroscopy 2006


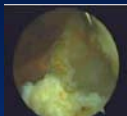
Technique

- ✓ Debridement flaps
 - ✓ Mechanical basket forceps / shaver
 - ✓ Radiofrequency ?
 - ✓ Avoid chondrectomy / stable cartilage Kelberine SFA 1995
- ✓ LLR with radiofrequency Martens Acta Ortho Belg 1990
Yercan CORR 2005
Paulos Arthroscopy 2008
- ✓ Lateral facetectomy



Technique

- ✓ Scope @ anteromedial portal = spacer
- ✓ Needles
- ✓ Burr / spurs
- ✓ Electraucautery @ inferolateral portal
 - ✓ Small hole at the upper part
 - ✓ Subcutaneous tissue inflating

Literature

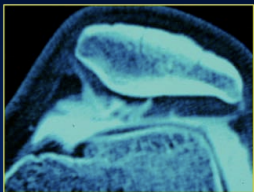
Open debridement + LLR / Arthritis

- ✓ Beltran Arthroscopy 2002
 - ✓ 33 knees : 60% painfree @ 31 mths
- ✓ Martens Acta Ortho Belg 1990
 - ✓ 90% good or mild @ 2 years
- ✓ Yercan Clin Orthop 2005
 - ✓ 11 cases @ 8 years sustained improvement

Literature

Arthroscopically done

✓ **Indication?** Osborne JBJS 1982
Unneberg Arch Orthop Trauma Surg 1988
Ogilvie-Harris 1984



Literature

Arthroscopically done / Arthritis

- ✓ **Aglietti** Arthroscopy 1989
✓ 6 cases failure @ 4 years
- ✓ **Jackson** Arthroscopy 1991
✓ 39 cases 56% satisfied @ 3,5 years 31% resurgery
- ✓ **Ewing** in Mac Ginty 1991 Raveb Ed
✓ 78% good results @ 6 years
- ✓ **Landsiedl** Z Ortop Ihre Grenzeb 1992
✓ 56% good @ 3,5 years

Literature


Arthroscopically done / Arthritis

- ✓ **Kelberine, Christel & SFA** SFA 1995
✓ 50 cases 60% good @ 5 years
- ✓ **Aderinto** Arthroscopy 2002
✓ 53 knees LLR (some FT arthritis included)
✓ Results worthwhile @ 31 mths, 4 TKA, 41% dissatisfied
- ✓ **Alemdaroglu** The knee 2008
✓ LLR 35 patients early results from 3 months stable to 2 years

Literature

Combined open and arthro

- ✓ **Paulos** Arthroscopy 2005
✓ 88% satisfied @ 5 y endure beyond
✓ with 9 patients delayed UKA for 3 Y

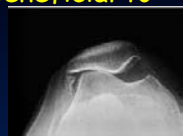



Severity of chondral damages?

- ✓ **No relation** Donnel The Knee 2007
Alemdaroglu The Knee 2008
- ✓ **Better results in low grades** Osborne JBJS 1982
Shea Arthroscopy 1992
Panni Arthroscop 2005
- ✓ **Better results in severe grade** Unneberg Acta Ortho Traua Surg 1988
Aderinto Arthroscopy 2002

Conclusion

- ✓ Arthroscopy can be beneficial to treat PF arthritis
- ✓ Without instability
- ✓ Procedure reliable
- ✓ Temporary benefit
- ✓ Results unpredictable

Doesn't burn any bridge