

Val d'Isère 2012
4th Advanced Course on Knee Surgery

**Acute multiligament injuries:
 Combined lesions:
 bony – neurovascular - cutaneous**

Prof. Dr. Romain Seil, Prof. Dr. Torsten Gerich

Dept. of Orthopaedic Surgery  Centre Hospitalier Luxembourg


Epidemiology



Always consider possible knee dislocation:
 majority reduced spontaneously !

Wilson TC & Johnson DL, Op Tech Sports Med 2003

Increase of severe knee injuries




Origin:

- sports (47 %)
- traffic (32%)
- other (21%)

Engebretsen L, Knee Surg Sports Trauma Arthrosc 2009


**Knee dislocations:
 injury mechanism**



- High energy
 - Motorbike, fall > 1,5 m
- Low energy
 - Sports, fall < 1,5 m
- Ultra low energy
 - Morbid obesity
 - Clinical exam difficult

➔ Minor mechanism may result in dislocation

**High energy knee dislocations
 & fracture-dislocations**



Dislocation at accident:
 High-energy trauma; rotation & shear forces

Highly unstable

High incidence of neurovascular and associated ligamentous injuries

TM Moore, CORR 1981

**Knee dislocations:
 injury mechanism**



Courtesy of B. Galaud, Caen, France


Knee dislocations

Schenk classification

Class	Description
KD I	Cruciates intact
KD II	ACL/PCL torn, LCL/MCL intact
KD III	ACL/PCL torn, MCL or LCL torn
KD IV	ACL/PCL/MCL/LCL torn
KD V	Periarticular fracture dislocation


Schenk RC, South Med J, 1992

Clinical examination




- Medical history
- Vascular status
- Neurological status
 - Peroneal nerve
- Soft-tissue status
 - Open
 - Closed
 - Compartment syndrome
- Ligament status
 - After fracture stabilization ?

Knee dislocation



- Closed reduction
- Avoid recurrence (open reduction ?)
- Reevaluate circulation
- Immobilize if necessary
- Brace
- CPM 4 x / day
- Definitive treatment after 7 – 10 days


Knee dislocation



Open reduction (rare)

- If closed reduction impossible
- Reevaluate circulation after reposition
- Stabilize fractures
- Repair collateral ligaments
- Secondary ACL/PCL reconstruction

Emergency operation



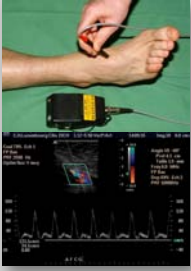
Strategy: several procedures

1. Save limb
2. Stabilize fractures
(here: short nail to avoid interference with ligament surgery)
3. Collateral ligaments
4. ACL/PCL

Emergency operation

- Compartment syndrome
- Vascular / neurologic injury
- Open fracture
- Major instability


Vascular status



- Palpation
- Doppler Ultrasound
- Angiography

Whiteside TE J Am Acad Orthop Surg 1996

Vascular status



- Coolness
- Pallor
- Cyanosis
- Delayed capillary refill
- Poor pulses
- Reduced ABI (< 0.9)

Mills WJ, J Trauma 2004

Vascular status

The Journal of TRAUMA: Injury, Infection, and Critical Care

The Value of the Ankle-Brachial Index for Diagnosing Arterial Injury After Knee Dislocation: A Prospective Study

William J. Mills, MD, David P. Barci, MD, FRCSC, and Patrick McNair, MD

Background: The risk of arterial injury with knee dislocation is well known. The most effective method for rapidly and accurately diagnosing arterial injury in this setting remains a topic of debate. Both physical examination and arteriography have been advocated, although each of these methods has its critics. The authors propose that the ankle-brachial index (ABI) can accurately predict whether patients with knee dislocations have sustained vascular injury.

Methods: A prospective study enrolled 38 patients with knee dislocation to evaluate for potential arterial injury using clinical pulse examination and ABI. Patients with an ABI lower than 0.90 underwent arteriography. Those with an ABI of 0.90 or higher were immobilized and admitted for serial examination and delayed arterial duplex evaluation.

Results: Of the 38 patients, 11 (29%) had an ABI lower than 0.90. All 11 had arterial injury requiring surgical treatment. The remaining 27 patients had an ABI of 0.90 or higher, none had vascular injury detectable by serial clinical examination or duplex ultrasonography. The sensitivity, specificity, and positive predictive value of an ABI lower than 0.90 were 100%. The negative predictive value of an ABI that reached 0.90 or higher was 100%.

Conclusions: The ABI is a rapid, reliable, noninvasive tool for diagnosing vascular injury associated with knee dislocation. Routine arteriography for all patients with knee dislocation is not supported.

Key Words: Ankle-brachial index, ABI, Knee dislocation, Vascular injury, Arteriography.

ABI > 0,90: no vascular injury
ABI < 0,90: Possible vascular injury

J Trauma 2004; 56:1261-1265


Vascular status

ABI > 0,9 (0,8)

- Normal vascularisation
- Arteriogram not needed
- Repeat exam several times during first days
 - Intimal tears can manifest late
 - Thrombosis

Johansen S, Oslo, Norway


Vascular status



Pulseless foot

- Immediate surgery
- Revascularisation
- No time waste with arteriogram
- CT angiogram ?

Vascular status




Vascular lesion

- Amputation rate – revascularisation
 - < 6 hours: 6 %
 - < 8 hours: 11 %
 - > 8 hours: 86 %

Engebretsen L, Johansen S, Oslo, Norway

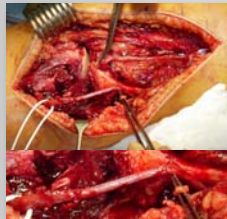
Neurological status



- Sensitivity
- Motricity
- Peroneal nerve
- DD compartment syndrome

Cattedra di Ortopedia e Traumatologia, Università di Padova - Ospedale Civile di Padova

Peroneal nerve lesion



- Posterolateral ligament injuries (15-30 %)
- < 30 % recover
- 45 % probability to have associated tibial nerve injury.
- if complete disruption consider early nerve transfer

Fanelli GC, 1995; LaPrade RF, 1997
Christel P, 2007

Cattedra di Ortopedia e Traumatologia, Università di Padova - Ospedale Civile di Padova

Soft-tissue status




- Skin lesions helpful for diagnosis (dashboard)

Gr. 3 PCL & bony PM capsule avulsion

Cattedra di Ortopedia e Traumatologia, Università di Padova - Ospedale Civile di Padova


Soft-tissue status



- Open
 - Gustilo classification
 - Tscherne class.
- Closed
- Compartment syndrome

Cattedra di Ortopedia e Traumatologia, Università di Padova - Ospedale Civile di Padova

Compartment syndrome




- Compartment pressure
- Diastolic blood pressure
- Dermatofasciotomy if $\Delta p < 30$ mm Hg

Whitesides TE J Am Acad Orthop Surg 1996

Cattedra di Ortopedia e Traumatologia, Università di Padova - Ospedale Civile di Padova

Compartment syndrome



Compartment syndrome in 414 tibia fractures:


- Proximal: 1,6 %
- Shaft: 8,1 %
- Distal: 1,4 %

Park S, J Orthop Trauma 2009

Cattedra di Ortopedia e Traumatologia, Università di Padova - Ospedale Civile di Padova


Compartment syndrome

- Fasciotomy of 4 compartments
- Repair collateral ligaments if skin closure possible (otherwise with VACuum closure)
- Late ACL/PCL reconstruction



Courtesy of T. Gerich, Luxembourg


Ligament status



- Exam under anesthesia
- Before / after fracture stabilization
- If in doubt intraop stress x-ray

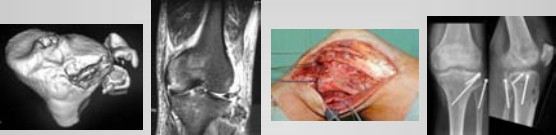
Bony status

Tscherne & Lobenhoffer tibial plateau fracture & fracture dislocation classification




Tscherne H, Lobenhoffer P (1993) Tibial plateau fractures. Management and expected results. Clin Orthop 292:87-100

Associated intraarticular injuries



	Plateau-fx	Fx-dislocations
ACL / PCL	4%	96%
MCL / LCL	15%	85%
Menisci	67%	33%


Stabilization



- Brace & CPM ASAP
- cast or external fixator in exceptional cases.

Here: external fixator in highly unstable knee in morbidly obese patient.

Bony status & associated injuries




Postop. 5 months

Bony status & associated injuries



Small text at the bottom: Centre Hospitalier de Luxembourg, Centre Hospitalier de Luxembourg

Open fracture



- Debridement
- Jet-lavage
- Minimal fixation
- VACuum closure

Small text at the bottom: Centre Hospitalier de Luxembourg, Centre Hospitalier de Luxembourg

Summary

- Systematic approach of these severe multiligament injuries
- Always consider knee dislocation
- Recognize emergency (save limb)
- Tibial plateau fracture dislocations frequently associated with severe ligament injuries

Small text at the bottom: Centre Hospitalier de Luxembourg, Centre Hospitalier de Luxembourg

15th ESSKA Congress
MAY 2-5, 2012
GENEVA/SWITZERLAND



www.esska-congress.org

Congress President: **ESSKA President**
E. Niek van Oort (The Netherlands)

Scientific Chairs
Prof. Patrick Beaulieu (Belgium) / Prof. Gertjan van't Hof (The Netherlands)

Congress Office
INTESCOGRESS
International Society of Sports Traumatology and Orthopaedics
www.intescogress.org


Venue
Geneva 2012

Early registration deadline:
February 10, 2012

Val d'Isère 2012 4th Advanced Course on Knee Surgery

Acute multiligament injuries: Combined lesions: bony – neurovascular - cutaneous

Prof. Dr. Romain Seil, Prof. Dr. Torsten Gerich

Dept. of Orthopaedic Surgery  Centre Hospitalier Luxembourg

Small text at the bottom: Centre Hospitalier de Luxembourg, Centre Hospitalier de Luxembourg