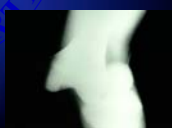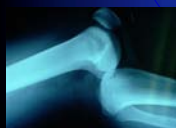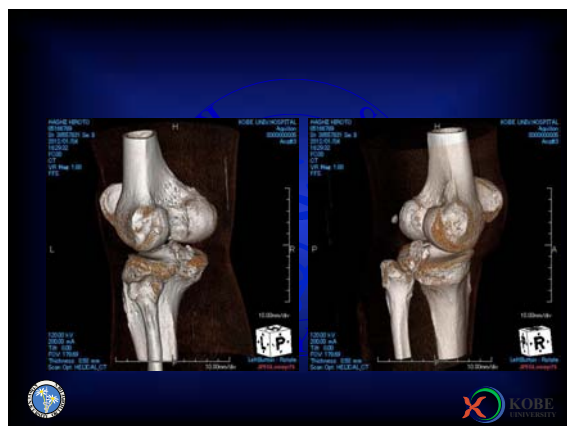


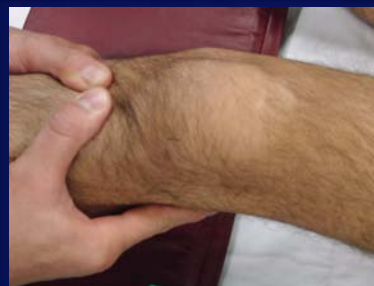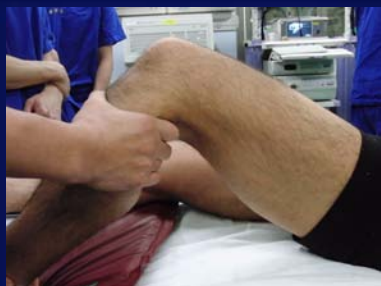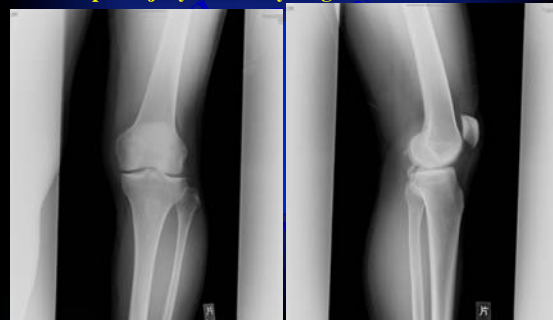Clinical cases presentation

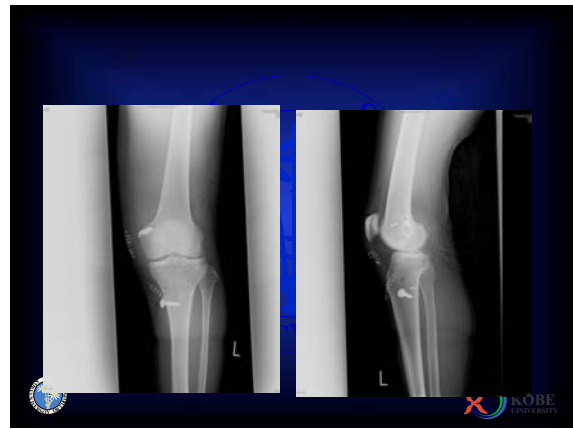
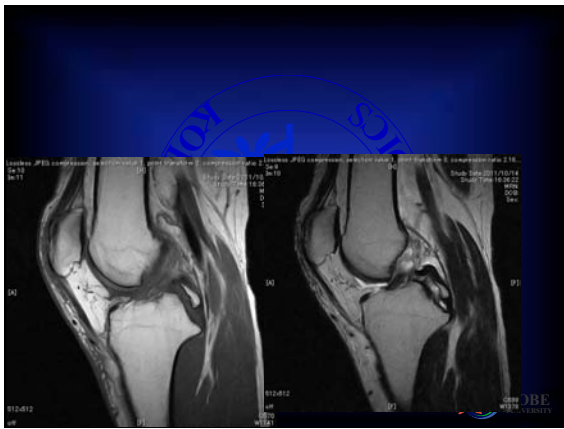
M. Kurosaka, MD
Kobe University



43yo male ;
Posterior medial instability 5months
postinjury with bony fragment



How do you approach this
bony lesion?



19 yo male
Traffic accident
Transferred at day 9 post injury

A composite image showing an X-ray of a knee joint on the left and several MRI scans on the right. The X-ray is labeled with 'R'.

Post injury day 10

A photograph of a knee joint with a visible laceration and swelling on the left, and an X-ray of a knee joint on the right labeled with 'R'. The X-ray shows a displaced fracture of the distal femur.

Debridement of ACL PCL




A photograph of a knee joint with a laceration on the left, and an arthroscopic view of the knee joint on the right showing the ACL and PCL.

Reduction could not be maintained without external fix

An X-ray of a knee joint showing an external fixator applied to the distal femur and proximal tibia. The text below the image reads: "No ligament reconstruction and 5mm increased translation but clinical outcome was not poor".


15 yo male Ski injury

Alpine skier
Fell in the steep downhill and bumped into the tree







Day 3 examination


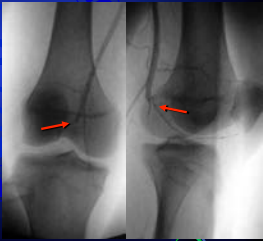


- ✓ posterior and lateral instability
- ✓ active movement of ankle and toe was deteriorated
- ✓ Paresthesia in the lower limb
- ✓ Vasularity seemed to be OK, however..



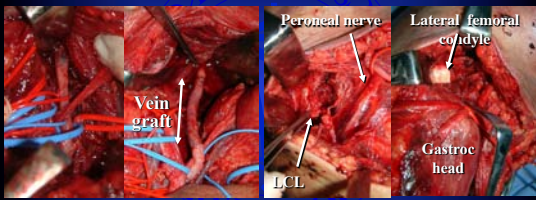
ADT PDT External Rotation Recursion test

Delayed popliteal artery occlusion was detected by angiography

Vascular repair and lateral corner repair



Intimal damage vascular graft LCL•Biceps, Gastroc

