

sports medicine
HANNOVER | THORSTRAUCH
excellence group

sports clinic
MEDICAL GROUP COOPERATION

Round table PCL

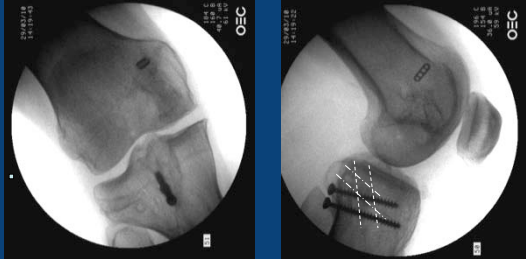
Christian Fink



sports clinic
MEDICAL GROUP COOPERATION

PCL Revision surgery

Case 1: 25 year professional downhill mountain biker,
2 PCL failures (hamstring, auto and allograft)



sports clinic
MEDICAL GROUP COOPERATION

Open inlay technique

Ideal for

- PCL reconstruction in case of severe (chronic) instability
- PCL Revision surgery



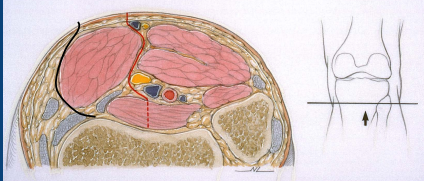


sports clinic
MEDICAL GROUP COOPERATION

Dorsal approaches to the knee

Posteromedial approach

Intragastroc. approach



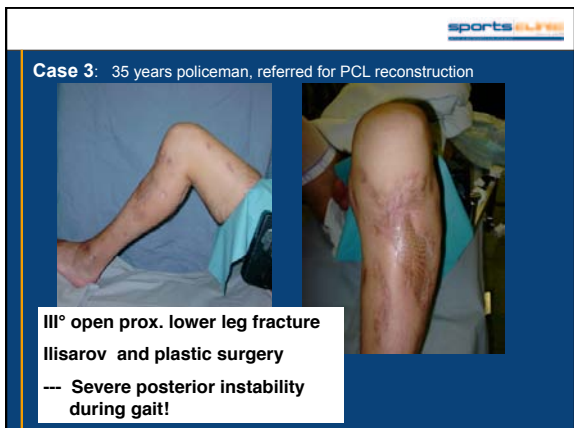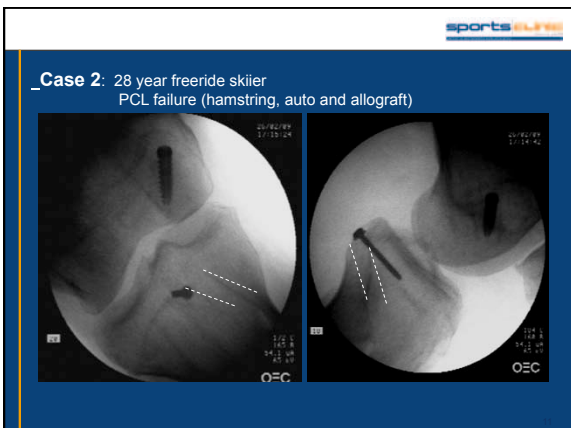
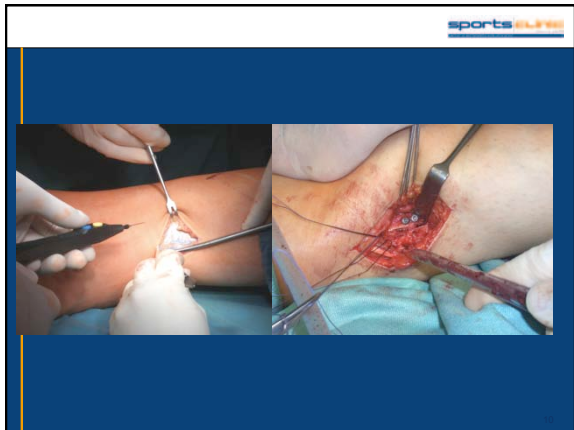
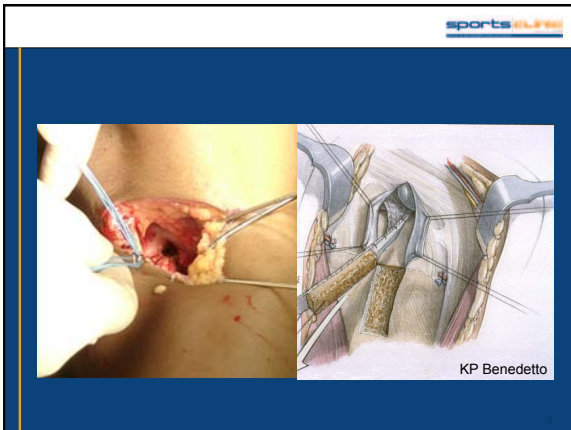
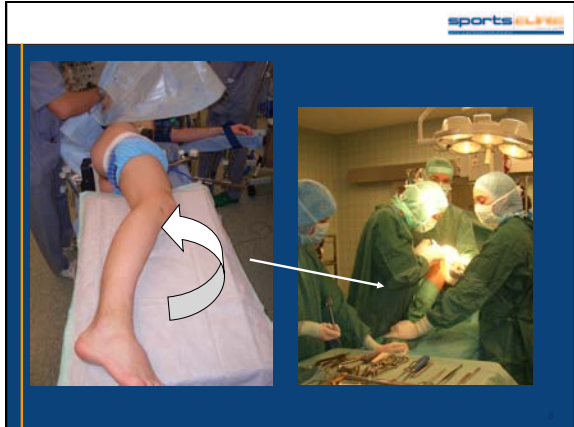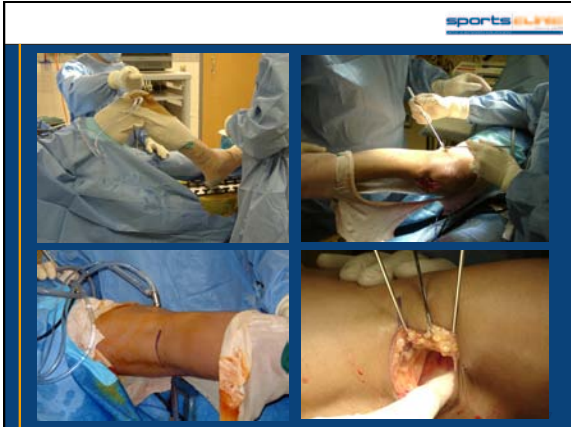sports clinic
MEDICAL GROUP COOPERATION

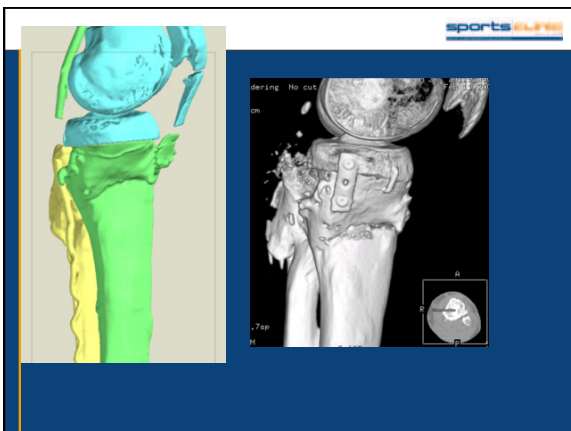
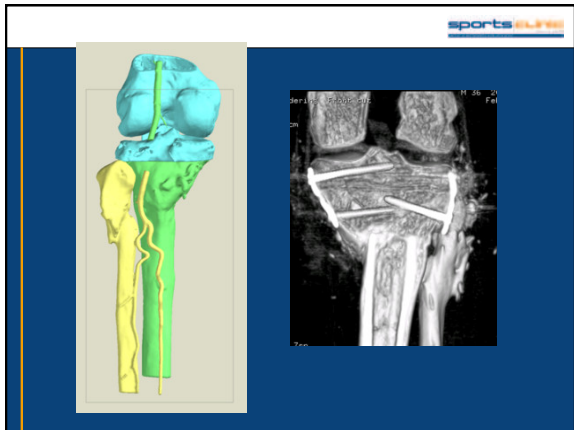
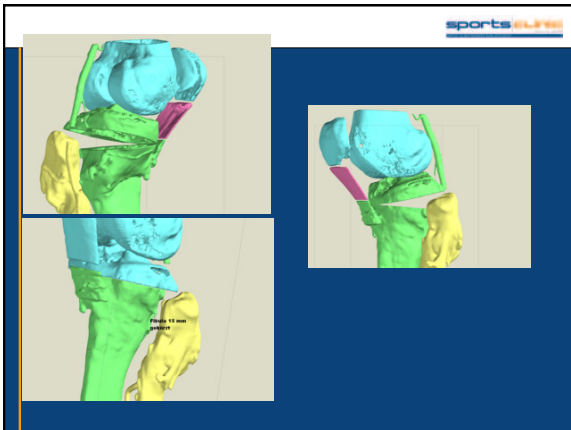
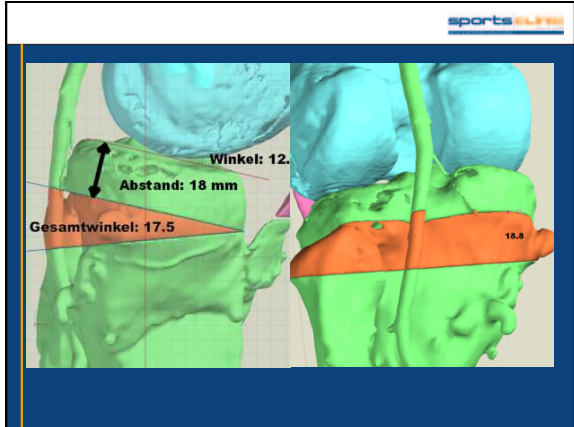
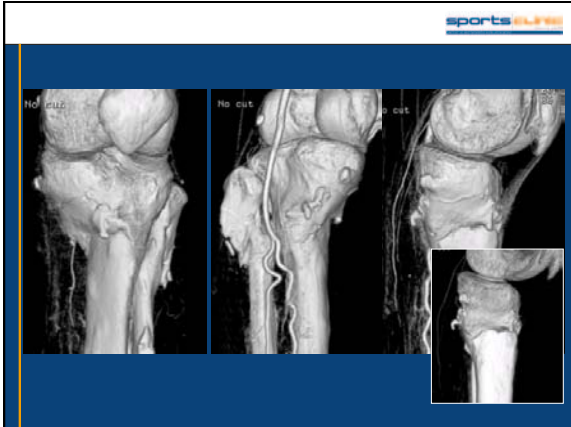
Posteromedial approach

- advantage:
 - doable in lateral decubitus position
 - you don't see any nerves and vessels
 - easier for additional posterolateral procedures

sports clinic
MEDICAL GROUP COOPERATION







sports|medicine
Hannover | Innsbruck

sports|CLINIC
Klinik für Orthopädie und Sportmedizin

Thank you!