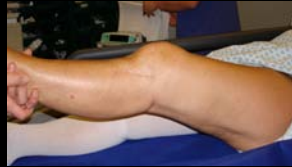

Posterior Capsular Release- Indications and Technique

Andy Williams

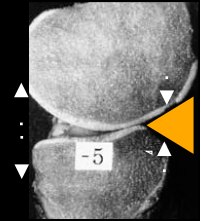
Fortius Clinic
&
Chelsea & Westminster
Hospital
London



Normal Extension

Static Limitation:

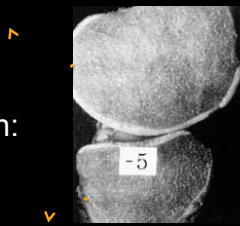- Anterior compression
 - Antero-medial joint surfaces and fat pad
- Posterior tension
 - capsule / hams / gastrocnemii



Normal Extension

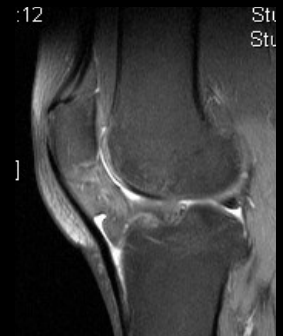
-Dynamic Limitation:

- Hamstrings
- Gastrocnemii



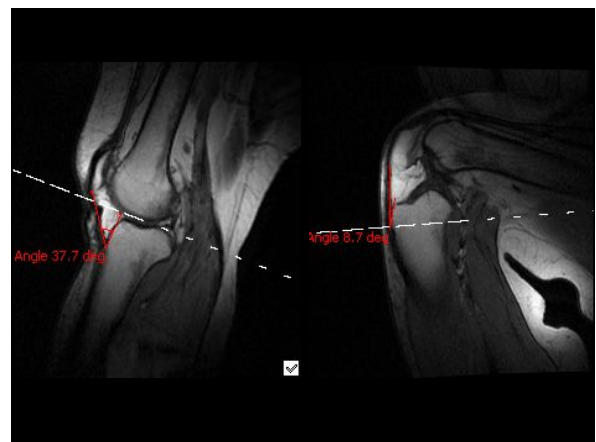
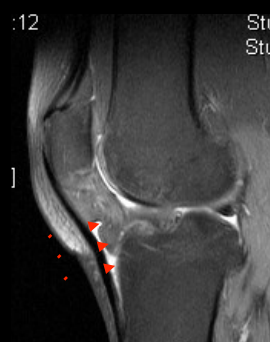Anatomy

- The 'Anterior Interval'

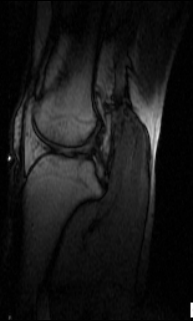

Anatomy

- The 'Anterior Interval'



The 'Anterior Interval'



Fixed Flexion

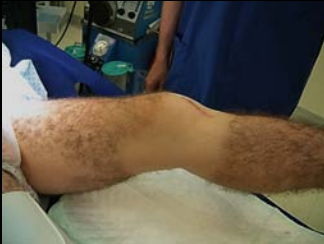Prevention Better than Cure!

- PHYSIO-
- full extension- active and passive
- patellar glides
- ice
- ITB / Calf / Hams stretches

Fixed Flexion

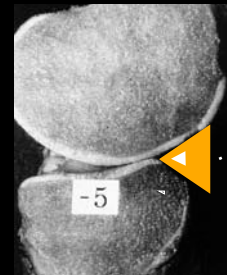
Prevention Better than Cure!

- do not operate until full extension for ACR



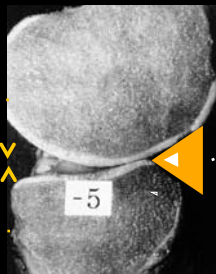
• Fixed Flexion

1. 'Door-jam' effect rigid fat pad



• Fixed Flexion

1. 'Door-jam' effect rigid fat pad
2. Posterior capsule + muscle contracture

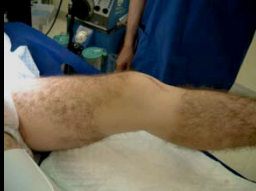

Rx Fixed Flexion:

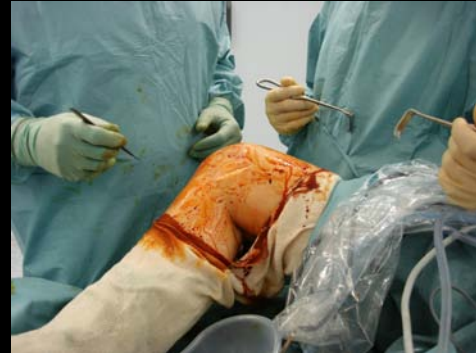- Fat Pad Release
- Posterior Capsular release
- [Osteotomy]

Indications for Posterior Capsule Release

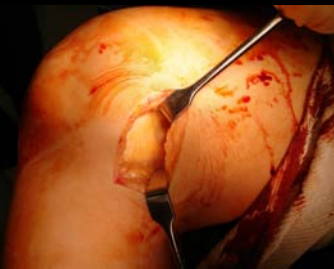- A quiet knee
- Failed non-surgical Rx
 - Active / Passive stretch
 - Prone hangs
 - Quads engagement
 - Patellar glides
 - Bracing
 - Serial casting
- Failed fat pad release



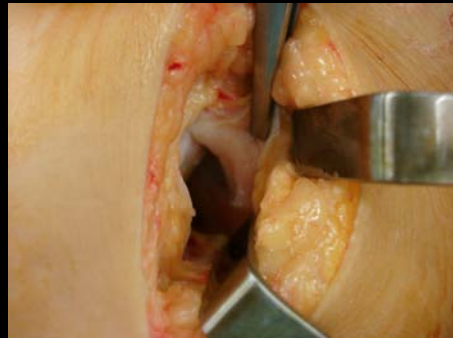Posterior Capsular Release



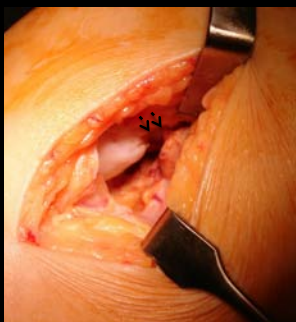
Posterior Capsular Release



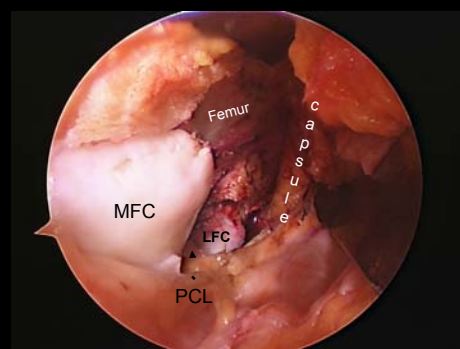
Posterior Capsular Release



Posterior Capsular Release



Posterior Capsular Release



Post-operative Care

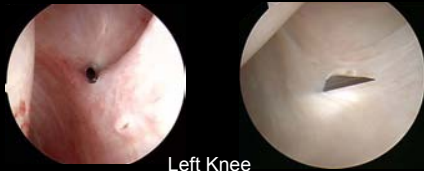- Extension brace at rest / night for up to 6 weeks
- Physio
 - Key: get full active extension
 - Prone hangs
 - Patellar glides
 - Passive stretches
 - Flex as tolerated

Results

- P. Lobenhoffer
 - 1996 Arthroscopic debridement + open post. release
 - 21 / 24 pts 10-30° longstanding FFD
 - None >5° FFD post-op
 - 2009 Open anterior + open post. releases
 - 86 / 121 average FFD 20°
 - None >5° FFD post-op

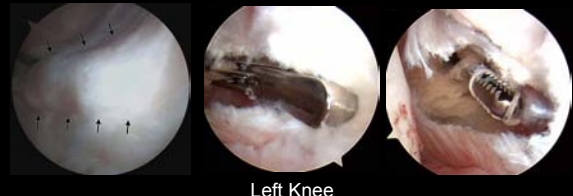Arthroscopic Posterior Capsular Release

- LaPrade et al 2008 KSSTA
 - 15 pts 15° FFD
 - Posteromedial arthroscopic releases
 - Post-op av 0.7°



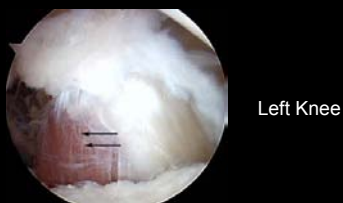
Arthroscopic Posterior Capsular Release

- LaPrade et al 2008 KSSTA
 - 15 pts: average 15° FFD
 - Posteromedial arthroscopic releases
 - Post-op av 0.7°



Arthroscopic Posterior Capsular Release

- LaPrade et al 2008 KSSTA
 - 15 pts: average 15° FFD
 - Posteromedial arthroscopic releases
 - Post-op av 0.7°



Posterior Capsular Release- a good trick!

