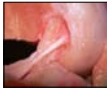
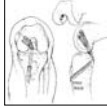
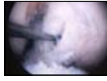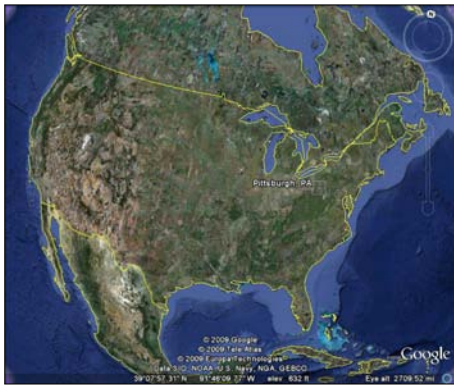4th Advanced Course on Knee Surgery
 Val d' Isere, France
 January 24, 2012

How I Do PCL Reconstruction

Christopher D. Harner, MD
 Blue Cross Endowed Professor
 Medical Director, Center for Sports Medicine
 Department of Orthopaedic Surgery
 University of Pittsburgh Medical Center



Greetings from Pittsburgh!



Pittsburgh: 2011 Most Livable City



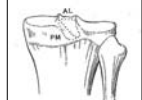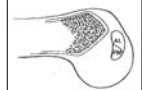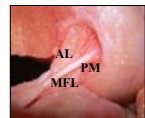Orthopaedic Sports Medicine Research Labs College & professional football operations Clinical offices and research center Hospital

University of Pittsburgh Sports Medicine Campus 2012

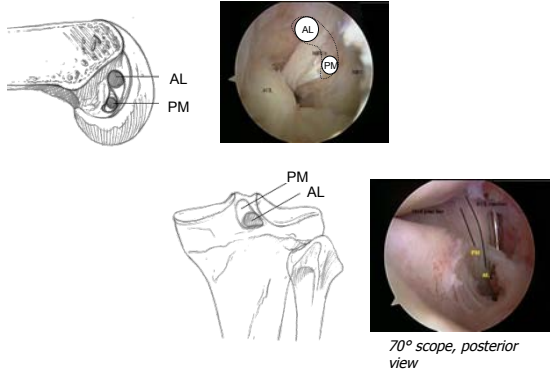
Current Surgical Approach

- 3 different techniques:
 - Single bundle (AL) - 30%
 - Double bundle (AL, PM) - 20%
 - Single bundle augmentation - 50%
- Approach depends on pattern of injury
- Insertion site anatomy is key!

Anatomy, Anatomy, Anatomy...



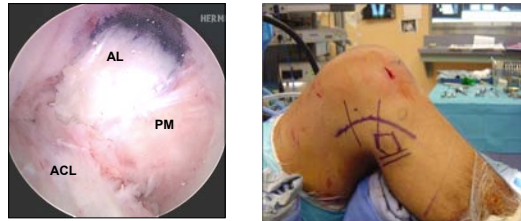
PCL Target Insertions



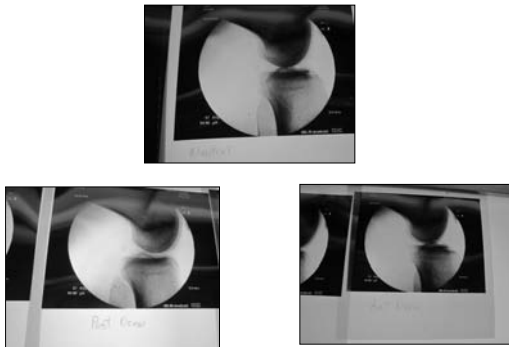
PCL Case Example

Single bundle PCL reconstruction (augmentation)


- AL torn, PM bundle intact
- Posterolateral corner reconstruction



EUA

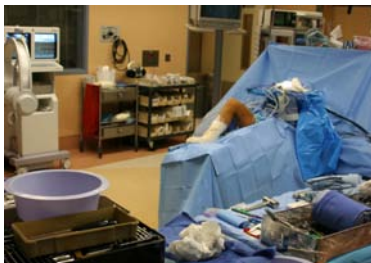

Preoperative Planning



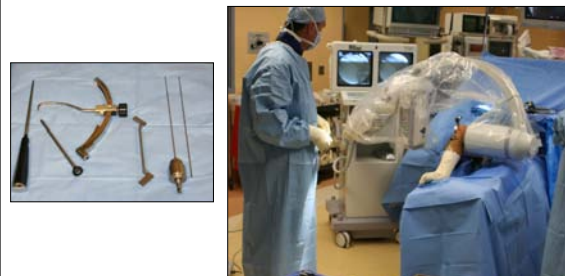September 29, 2010

Operative Set-up



No tourniquet
No leg holder
Intra op mini fluoro

PCL Tunnel Guides



Intra op fluoro

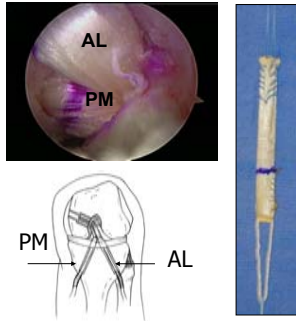
PCL Graft Choices

Allo – 70%

- Achilles tendon
- Tib ant

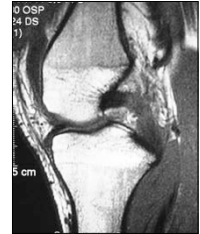Auto – 30%

- quad tendon
- younger patients



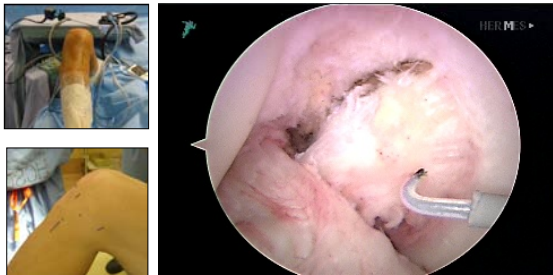
PCL Anterolateral (AL) Reconstruction

- 22 y/o baseball player
- 2 yrs s/p injury w/ instability
- EUA:
 - Grade II PCL and III PLC
- Arthroscopic findings:
 - Intact PM bundle
- Plan:
 - Anatomic AL bundle reconstruction w/quad tendon autograft
 - PLC reconstruction



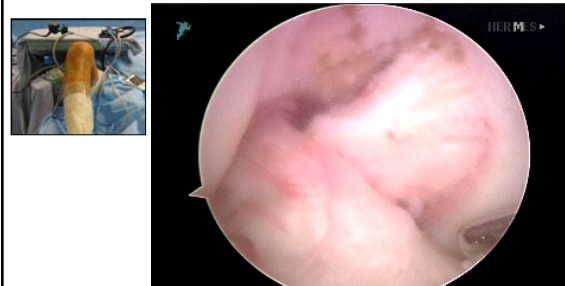
Anatomic AL Reconstruction

Define pathology: PM intact (right knee)



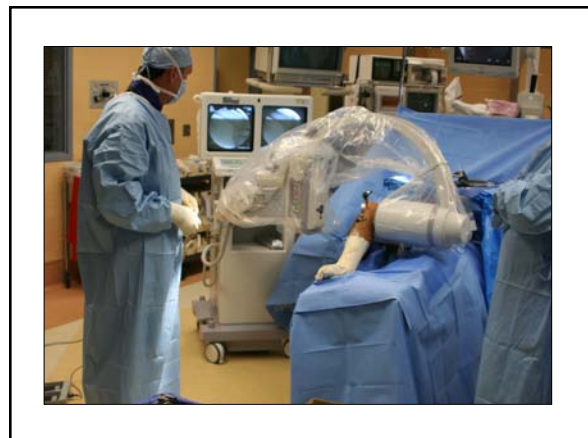
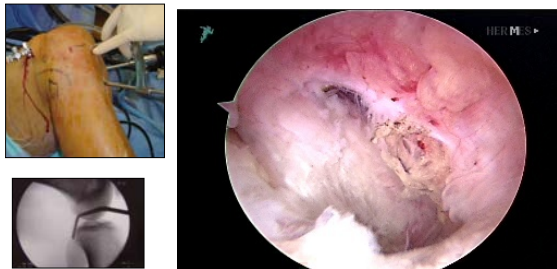
Anatomic AL Reconstruction

Tibial tunnel preparation



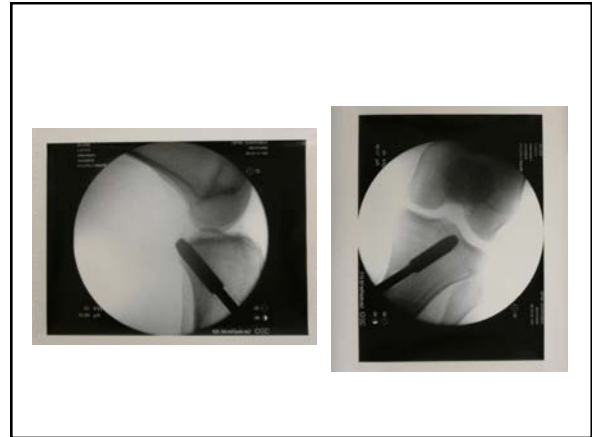
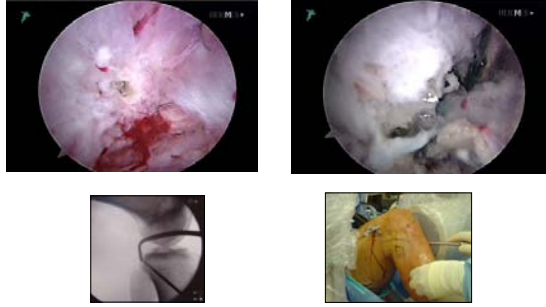
Anatomic AL Reconstruction

Tibial tunnel



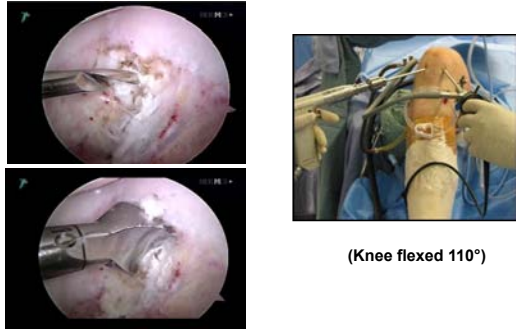
Anatomic AL Reconstruction

Tibial Tunnel



Anatomic AL Reconstruction

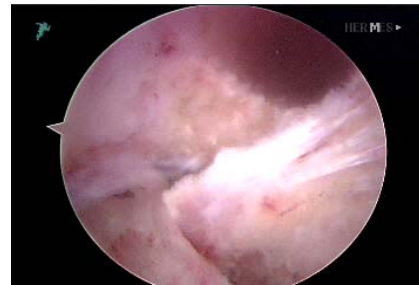Femoral tunnel drilled from lateral portal



(Knee flexed 110°)

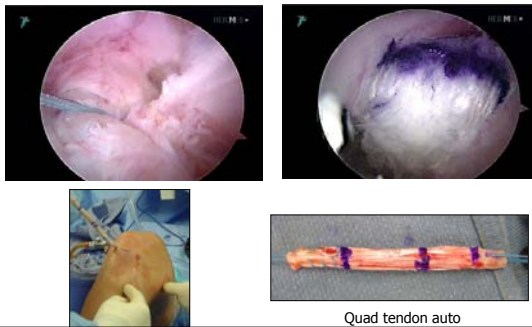
Anatomic AL Reconstruction

Final femoral tunnel



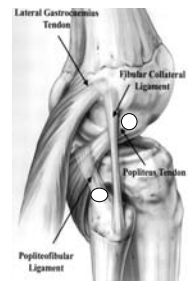
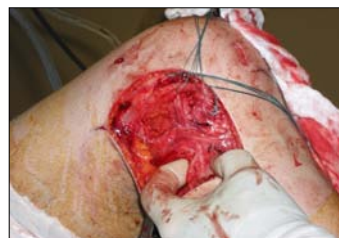Anatomic AL Reconstruction

Graft passage



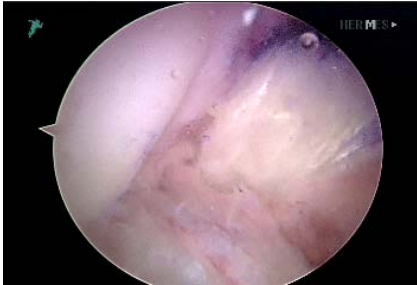Quad tendon auto

Anatomic Posterolateral Corner (PLC)



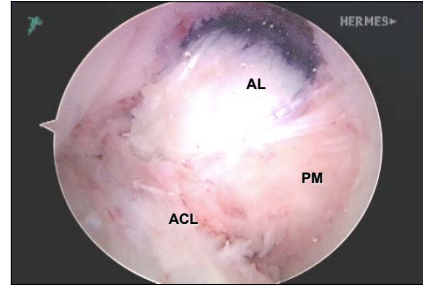
Anatomic AL Reconstruction

Final Augmentation



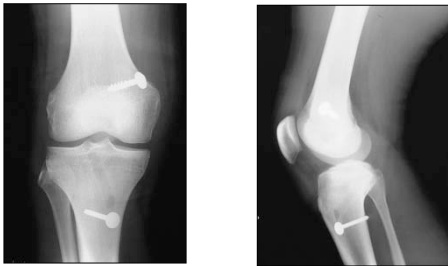Anatomic AL Reconstruction

AL bundle reconstruction with intact native PM



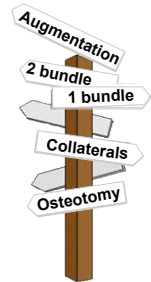
Anatomic AL Reconstruction

Post-op Xrays: AL case



Conclusions

- Not all PCL injuries are the same
- Most isolated PCL injuries are still treated non-operatively
- Decision regarding single bundle, double bundle and augmentation techniques are based on injury patterns and insertion site anatomy
- Remember to address all injured secondary restraints



Thank You

