

# Clinical Case 2

---

P. Landreau. Orthopaedic Surgeon

E. Almusa. Radiologist

Aspetar. Orthopaedic and Sports Medicine Hospital

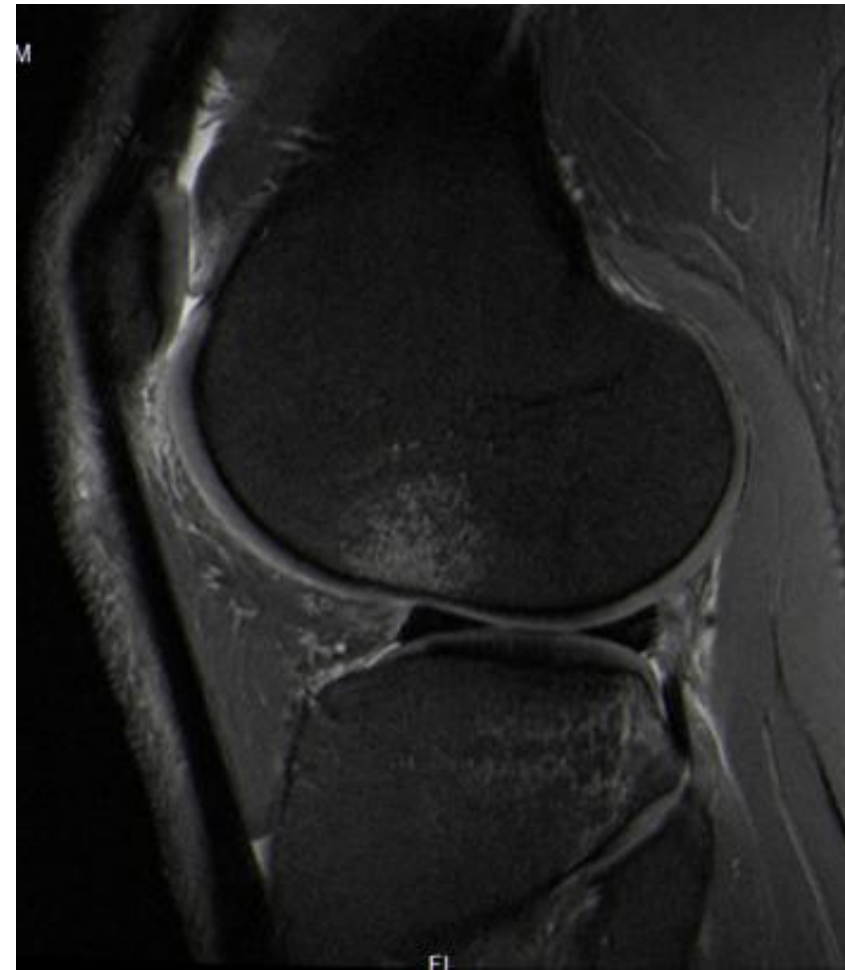
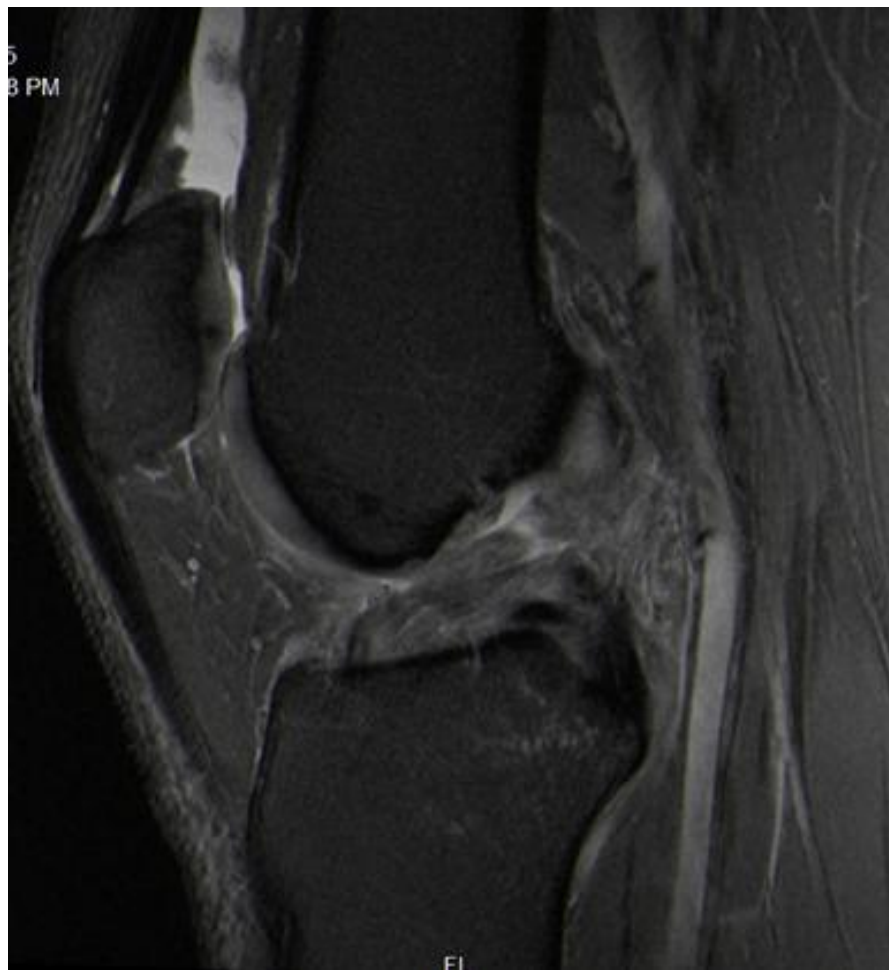
Doha

Qatar

## Case 2

---

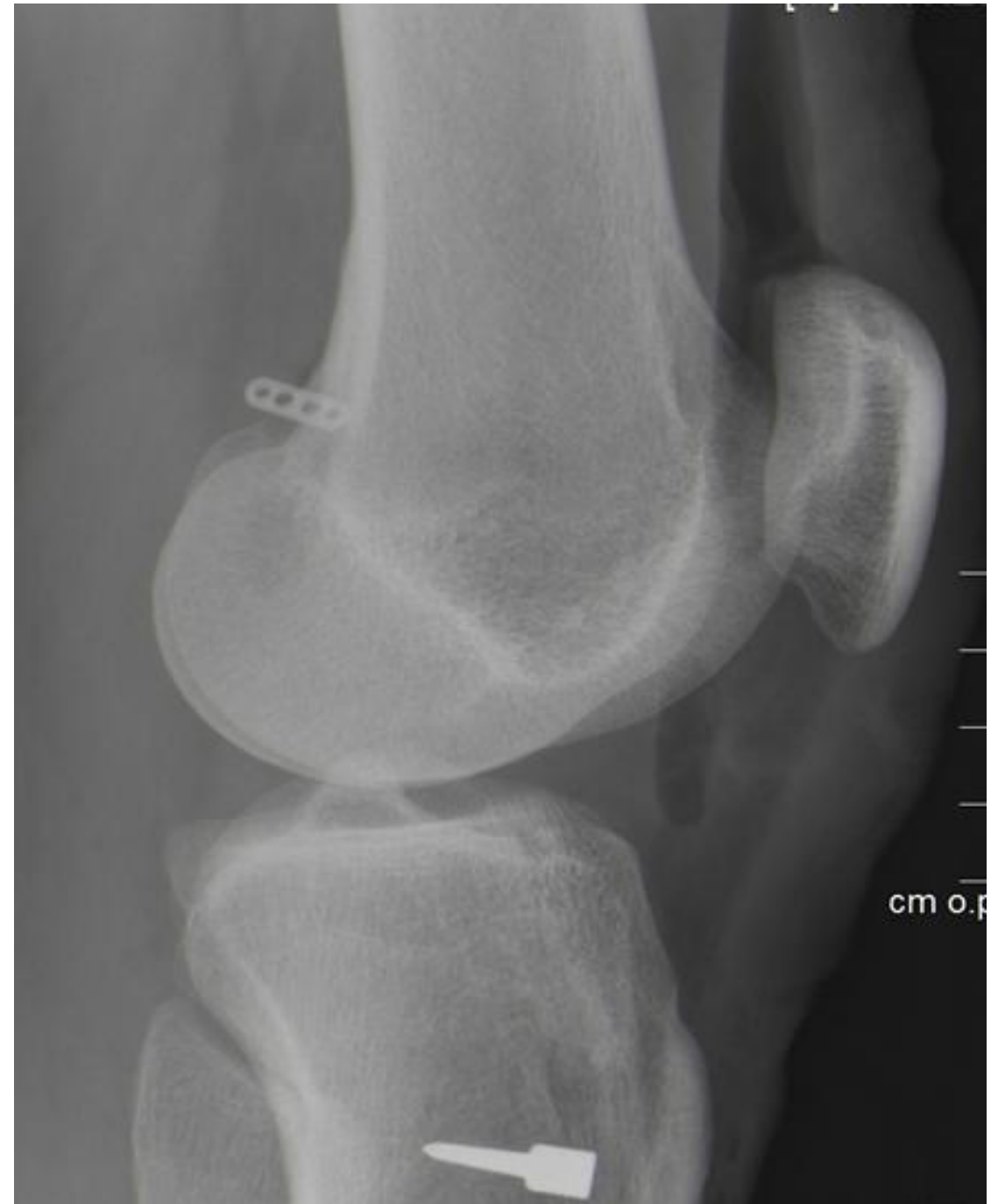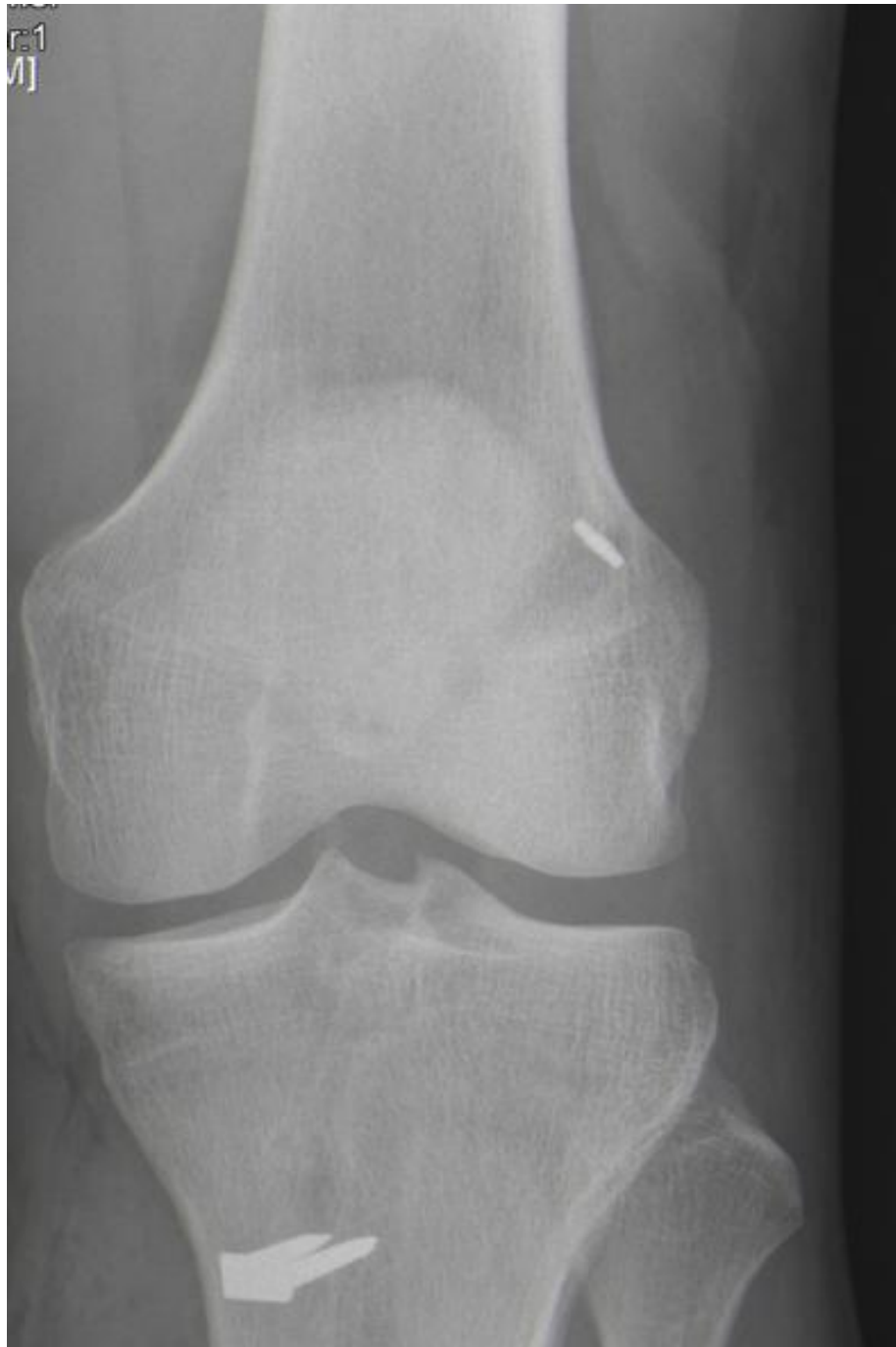- 35 y.o. professional football player.
- Left isolated ACL tear.



## Case 2

---

- Left ACLR quadruple Hamstrings



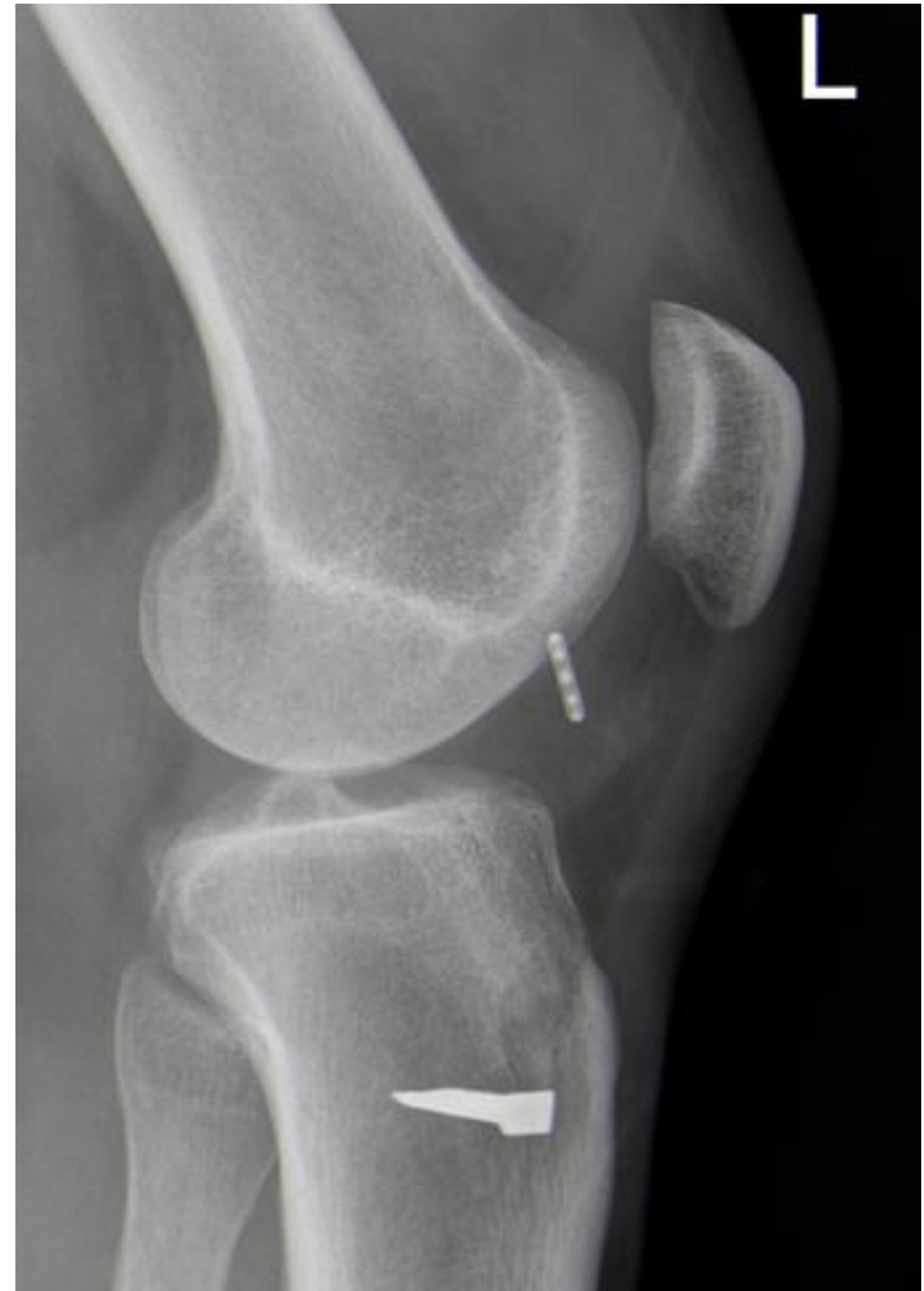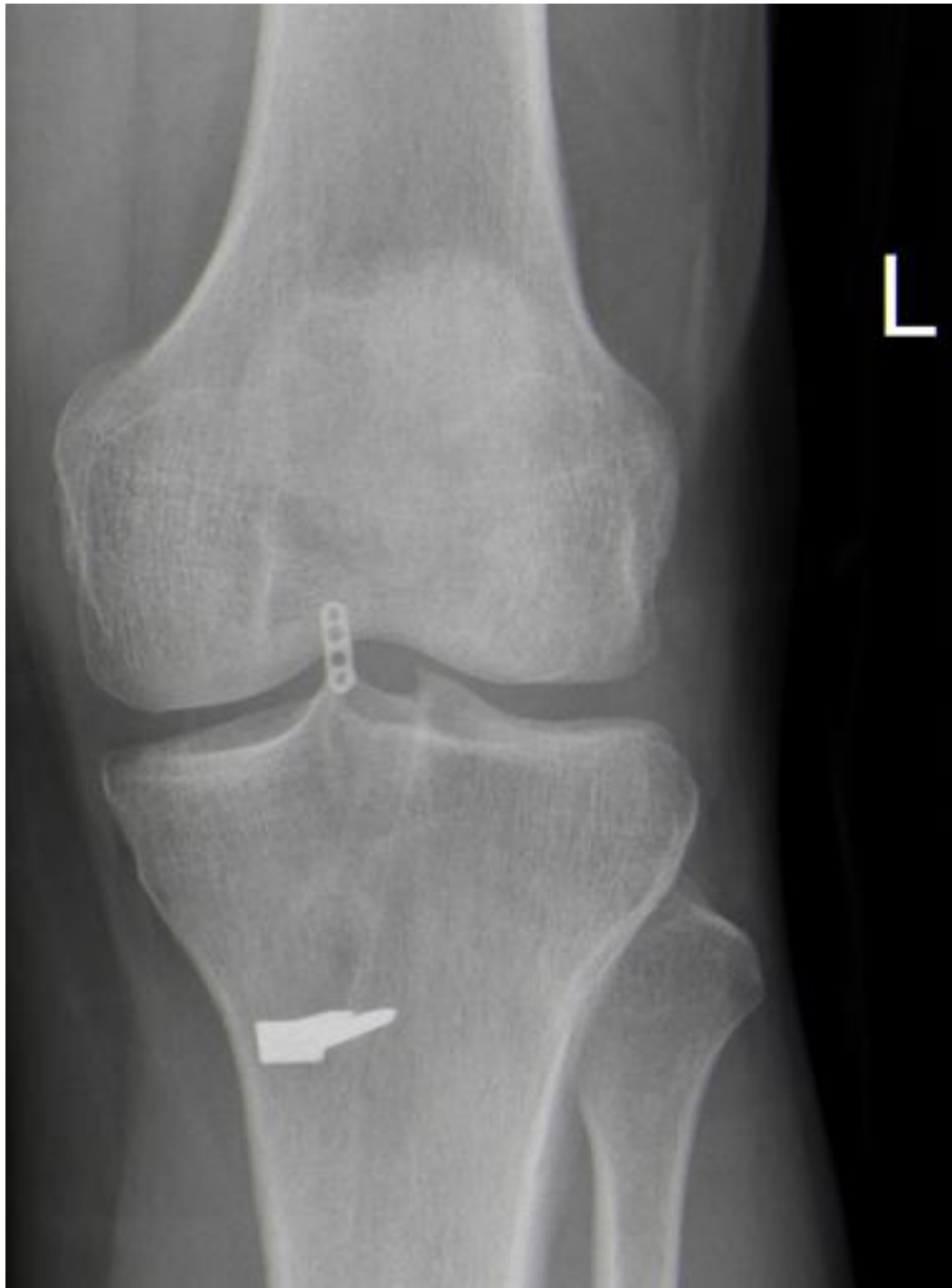## Case 2

---

- Initial phase unremarkable.
- 6 months after ACLR: Recurrent swelling. Instability.
- No reported injury.

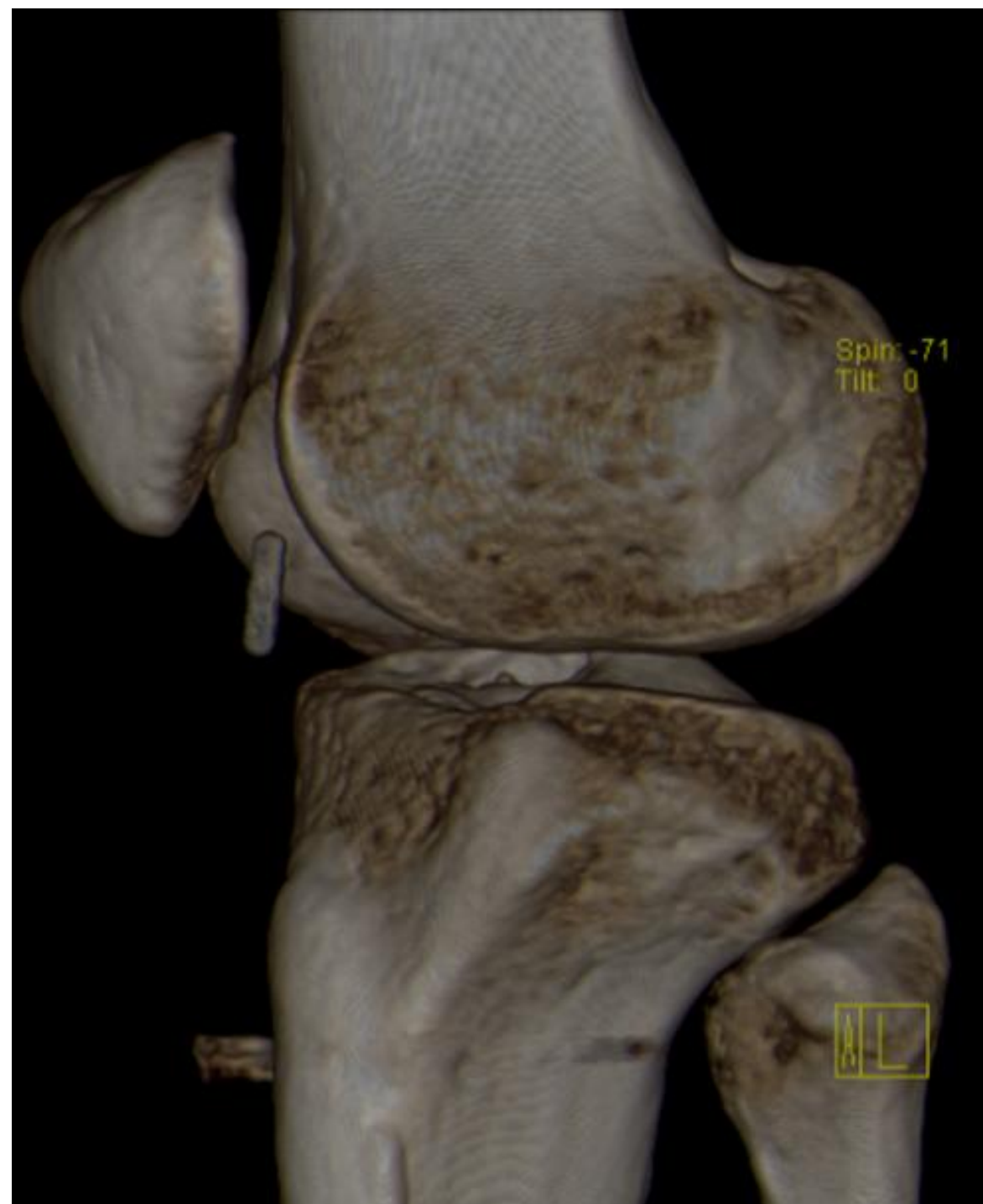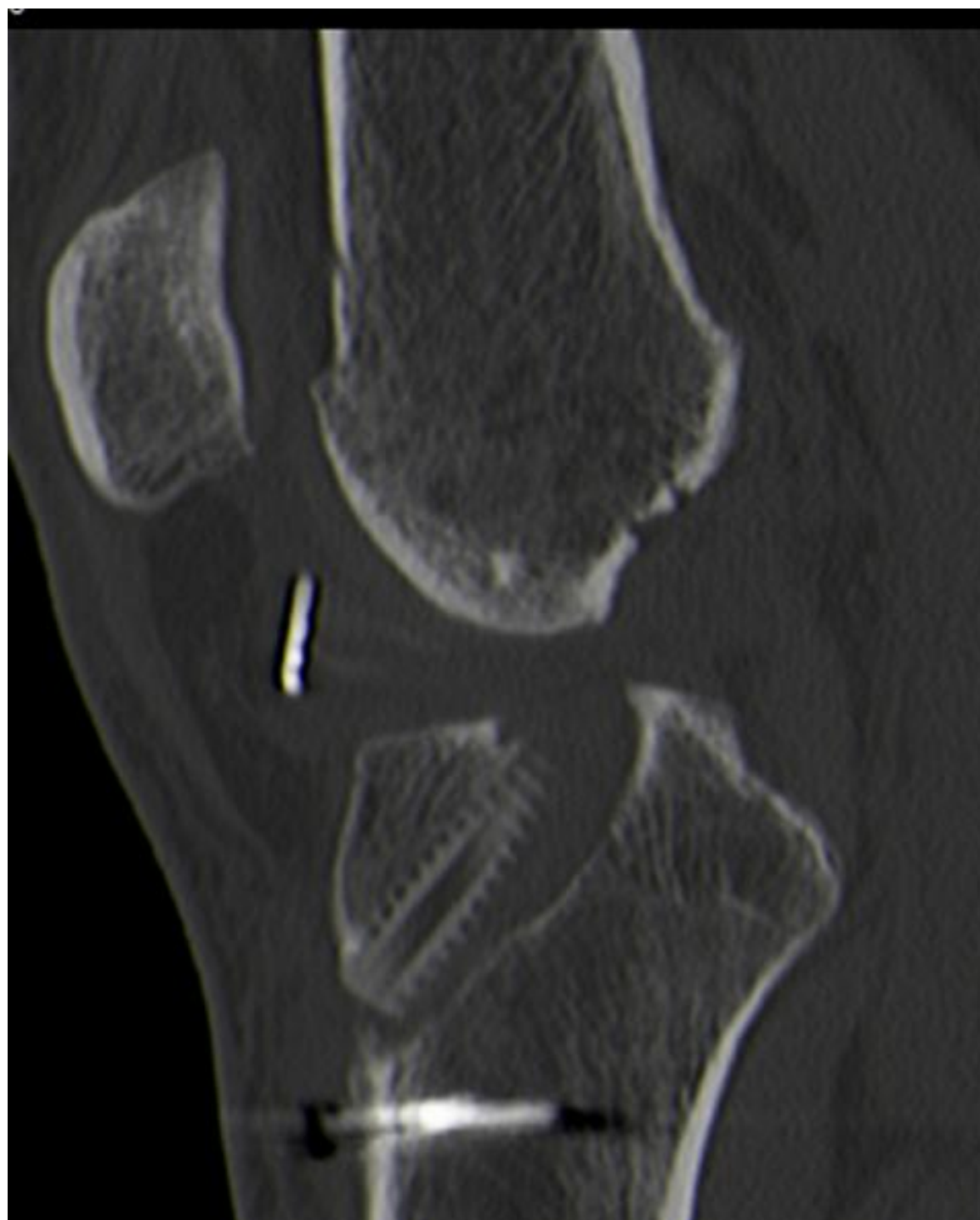## Case 2: 6 months

---



# Case 2

---



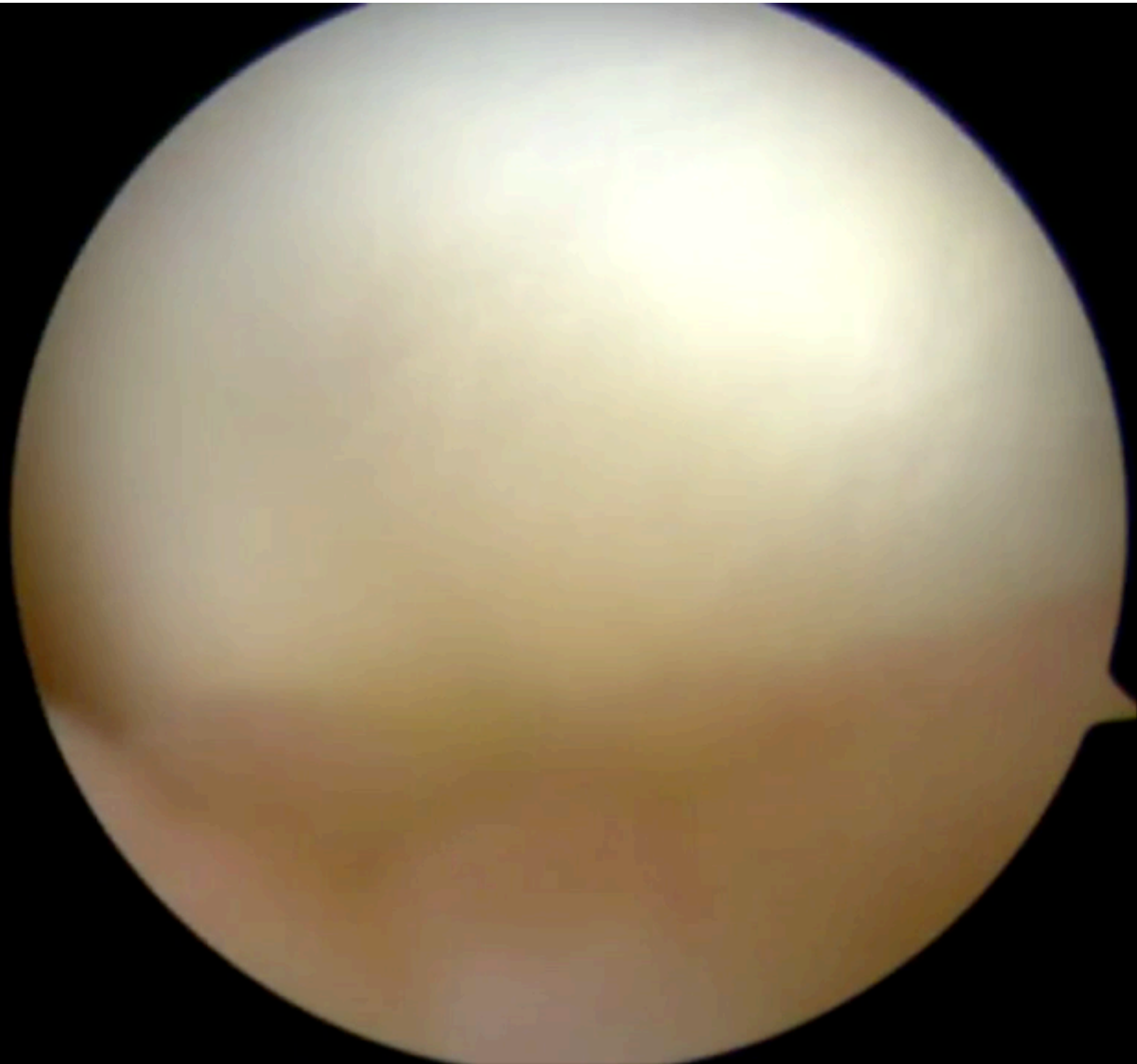
## Case 2

---

- What is your revision plan?
  - Use the same graft and new femoral fixation?
  - Remove the graft and revision using another graft?
  - Only combined procedure?
  - ...

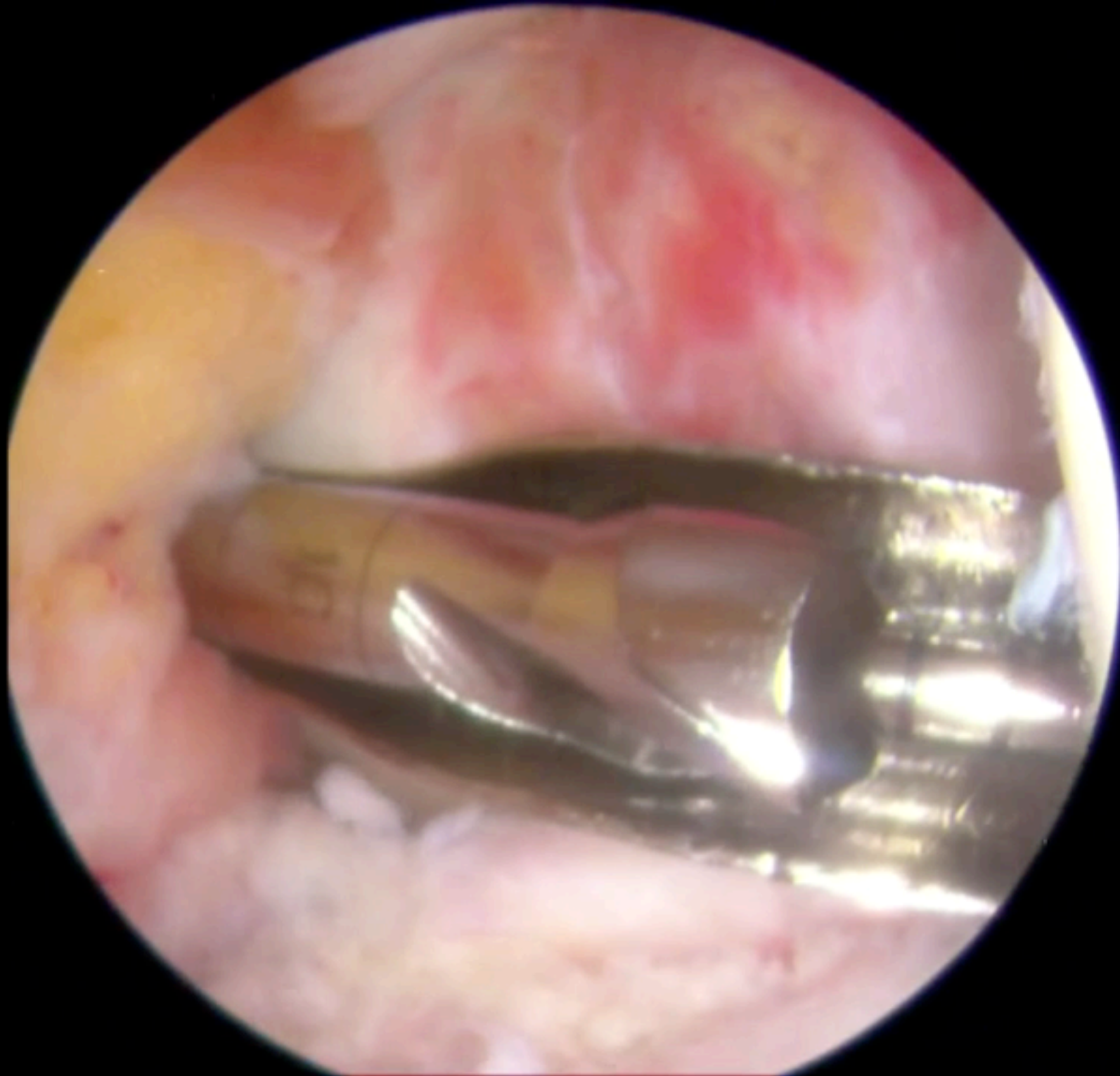

## Case 2





## Case 2



# Case 2

---

