



7TH Advanced Course on Knee Surgery
14th to 18th January 2018
Val d'Isère – France

What we can expect? Case presentation

Mike Carmont

Princess Royal Hospital

Shropshire, UK



Case Presentation

- 42 years old
- Male
- Owns taxi company
- Recreational competitive squash
- Weight 175Kg



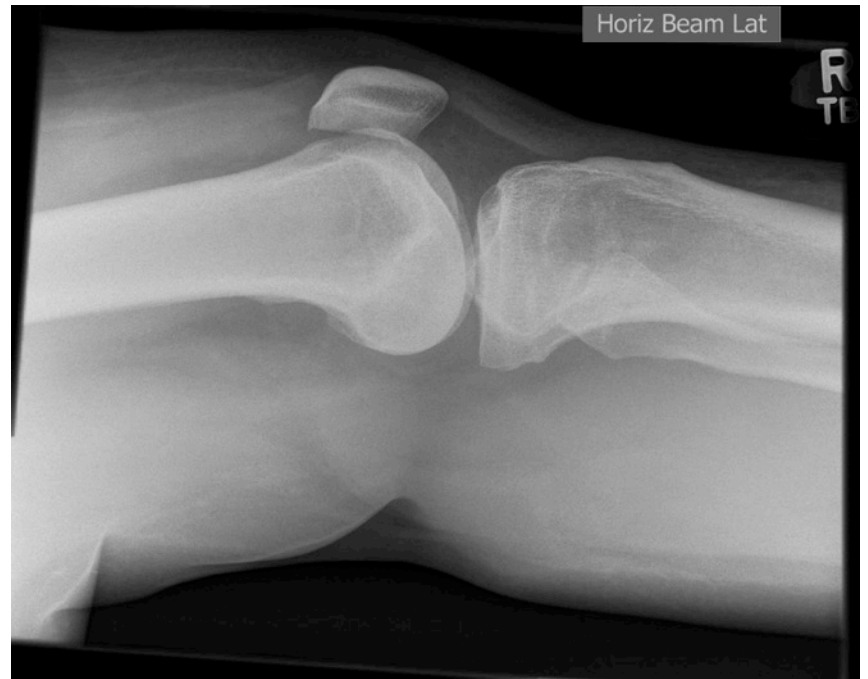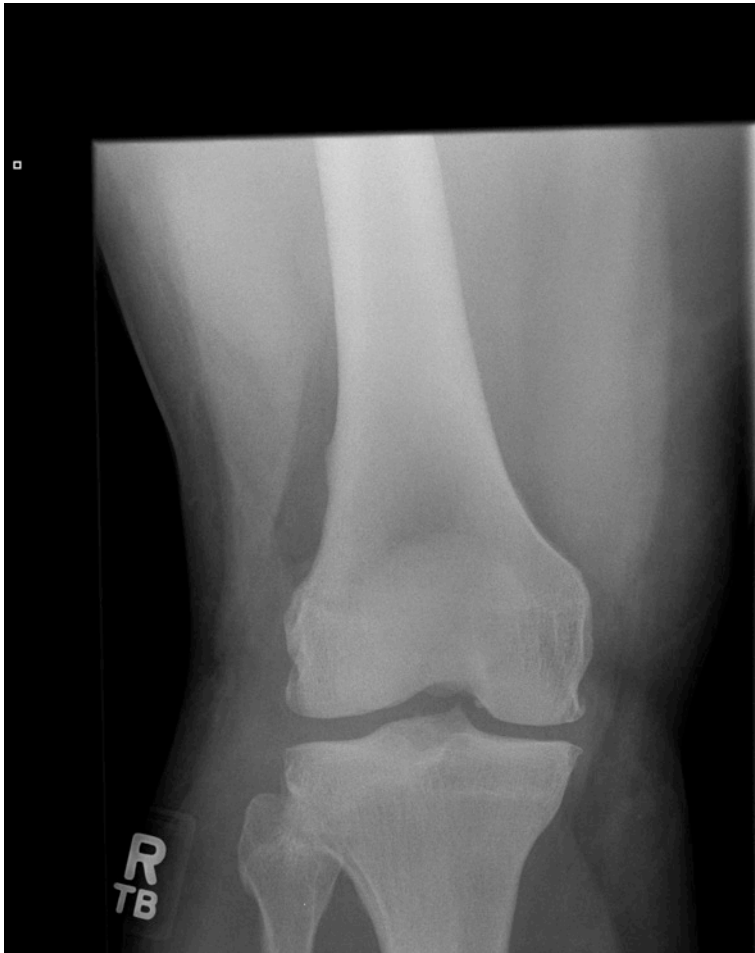Traditional Scottish Food



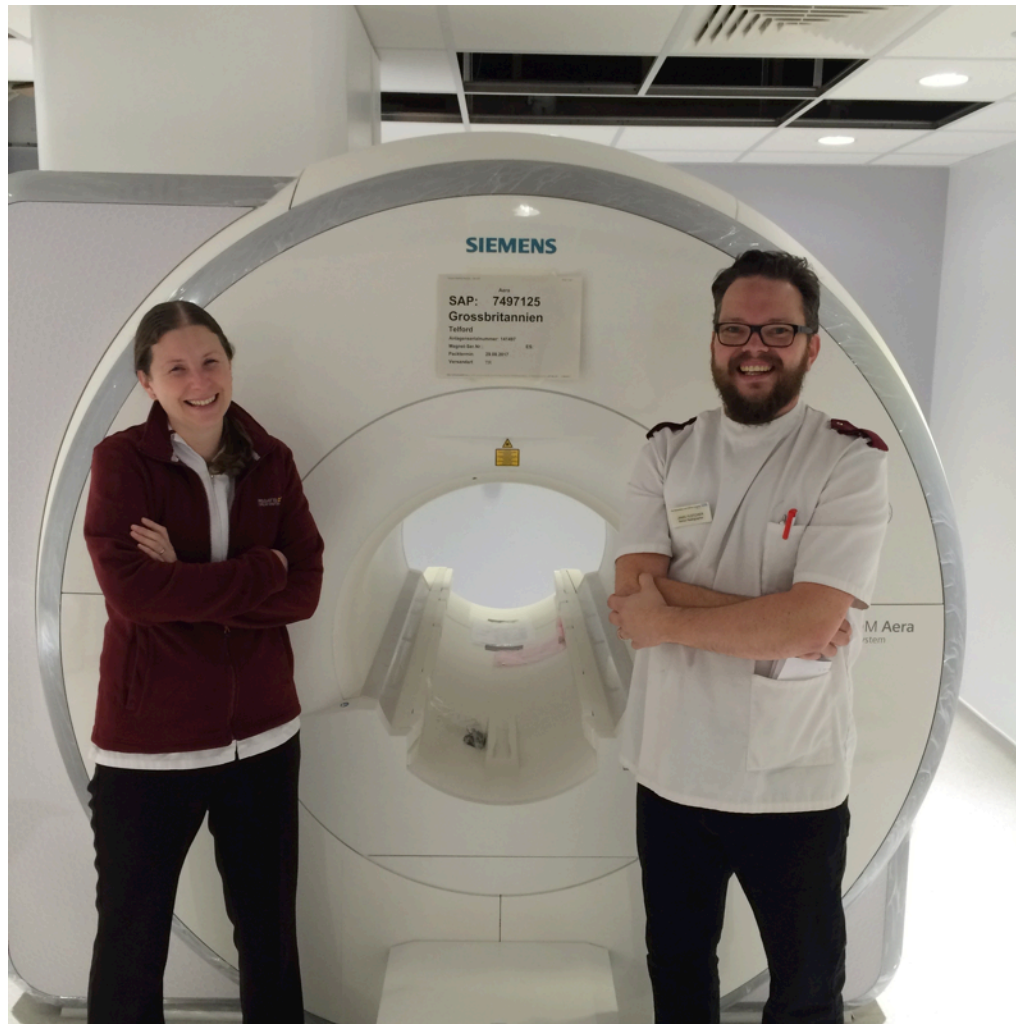Case Presentation

- 42 years old
- Male
- Owns taxi company
- Recreational competitive squash
- Weight 175Kg
- Shoe breaks
- Injures knee
- Painful knee
- Pulse present
- Dorsum foot anaesthesia
- Unable to dorsi flex ankle & extend toes

Radiographs



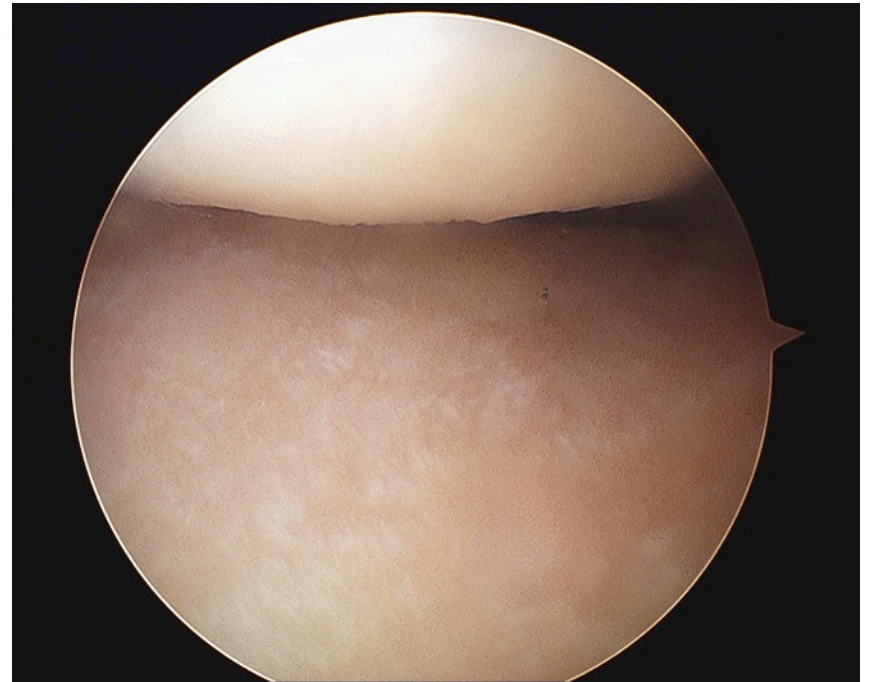
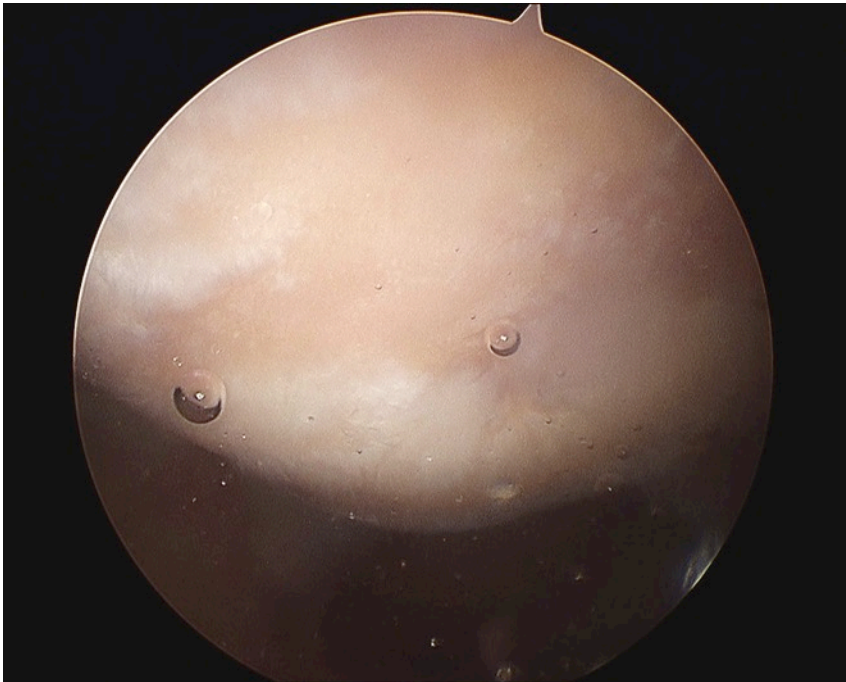
Too big MRI scanner



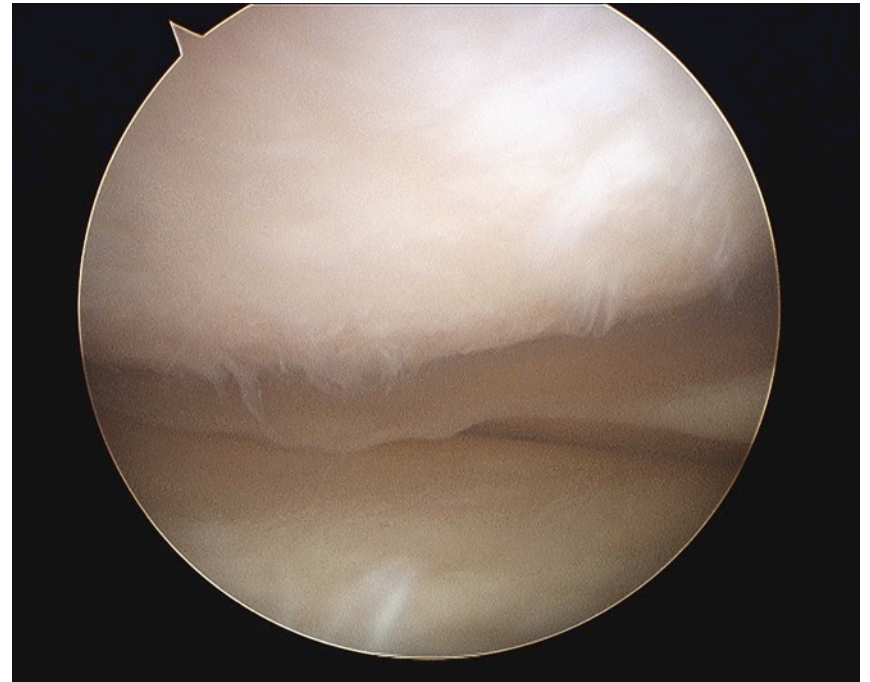
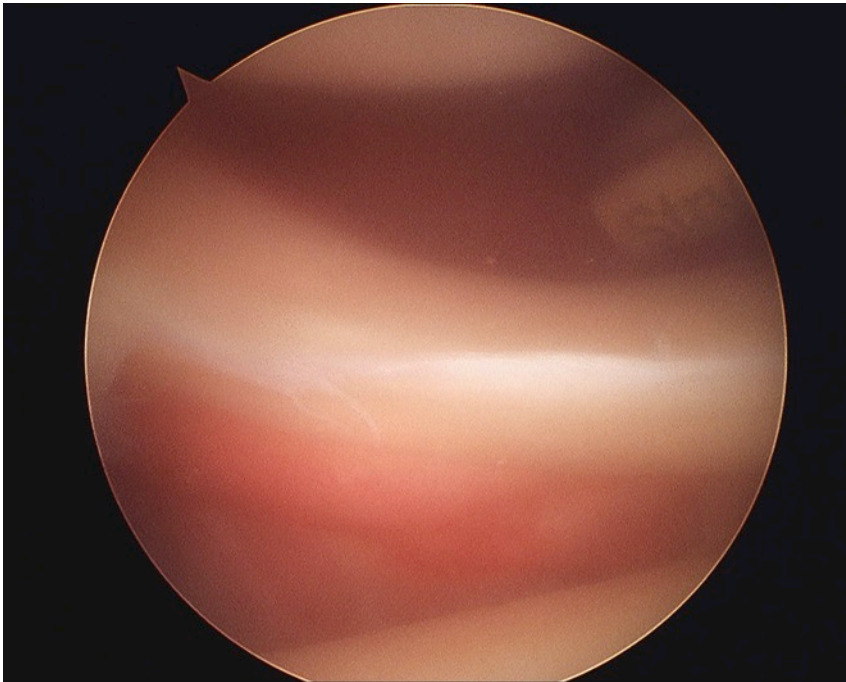
Nearest scanner



Preexisting OA



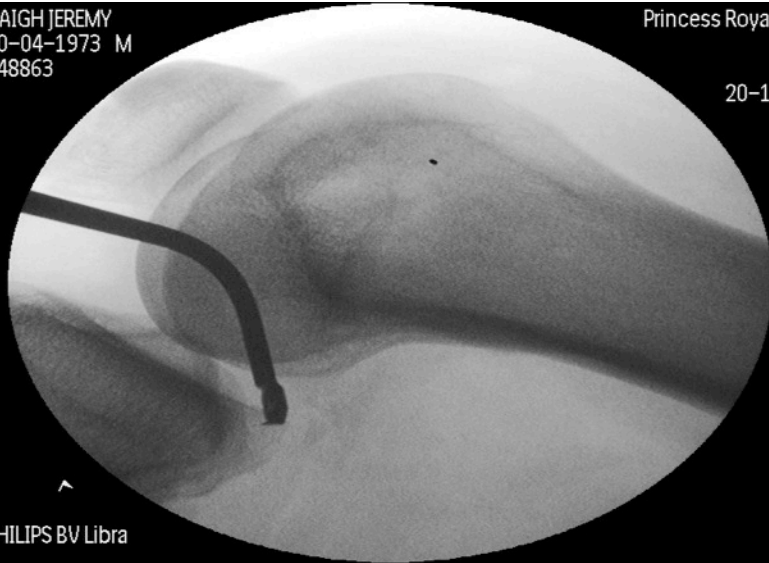
Increased LCL & PCL laxity



PCL Intra-operative Fluoroscopy

HAIGH JEREMY
20-04-1973 M
548863

Princess Royal Hospital Telfor
20-12-2012 13:04

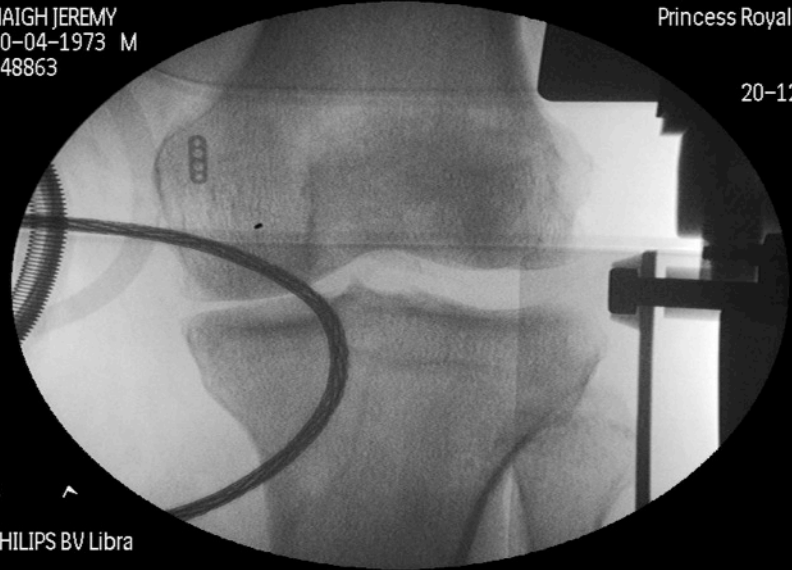


1
1
PHILIPS BV Libra

Princess Royal Hospital Telfor

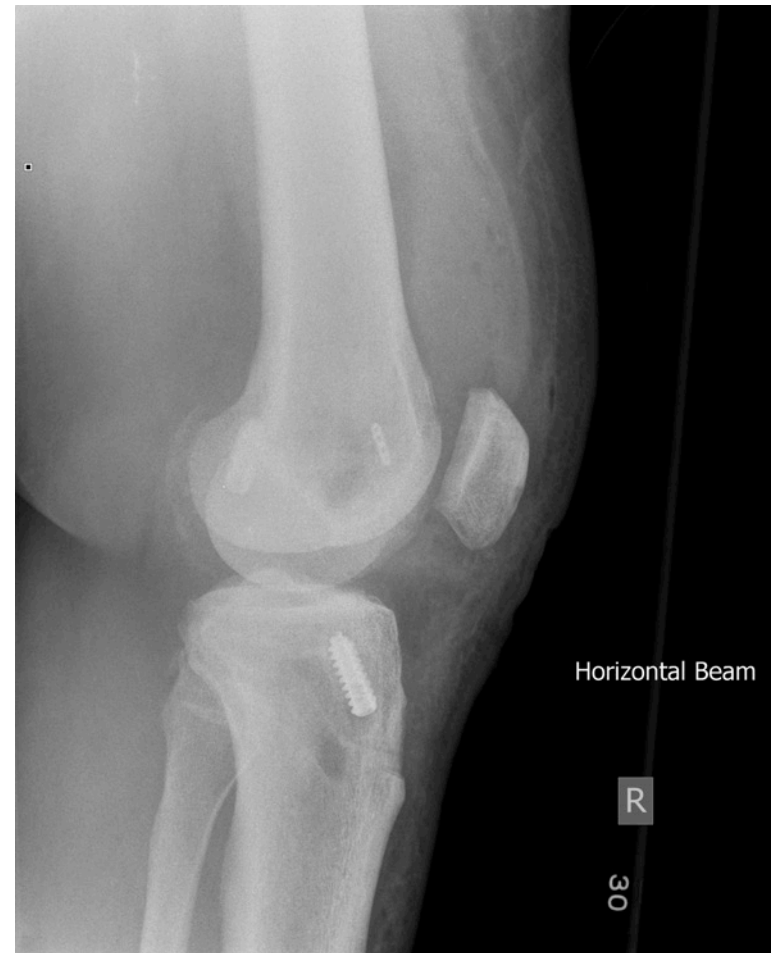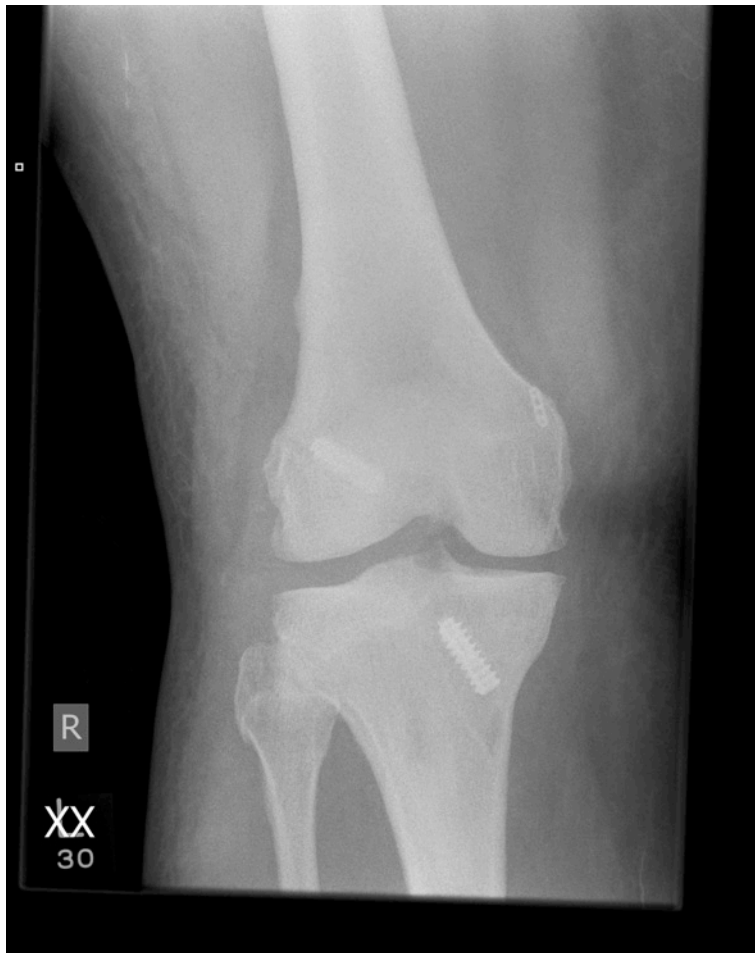20-12-2012 13:43

HAIGH JEREMY
20-04-1973 M
548863

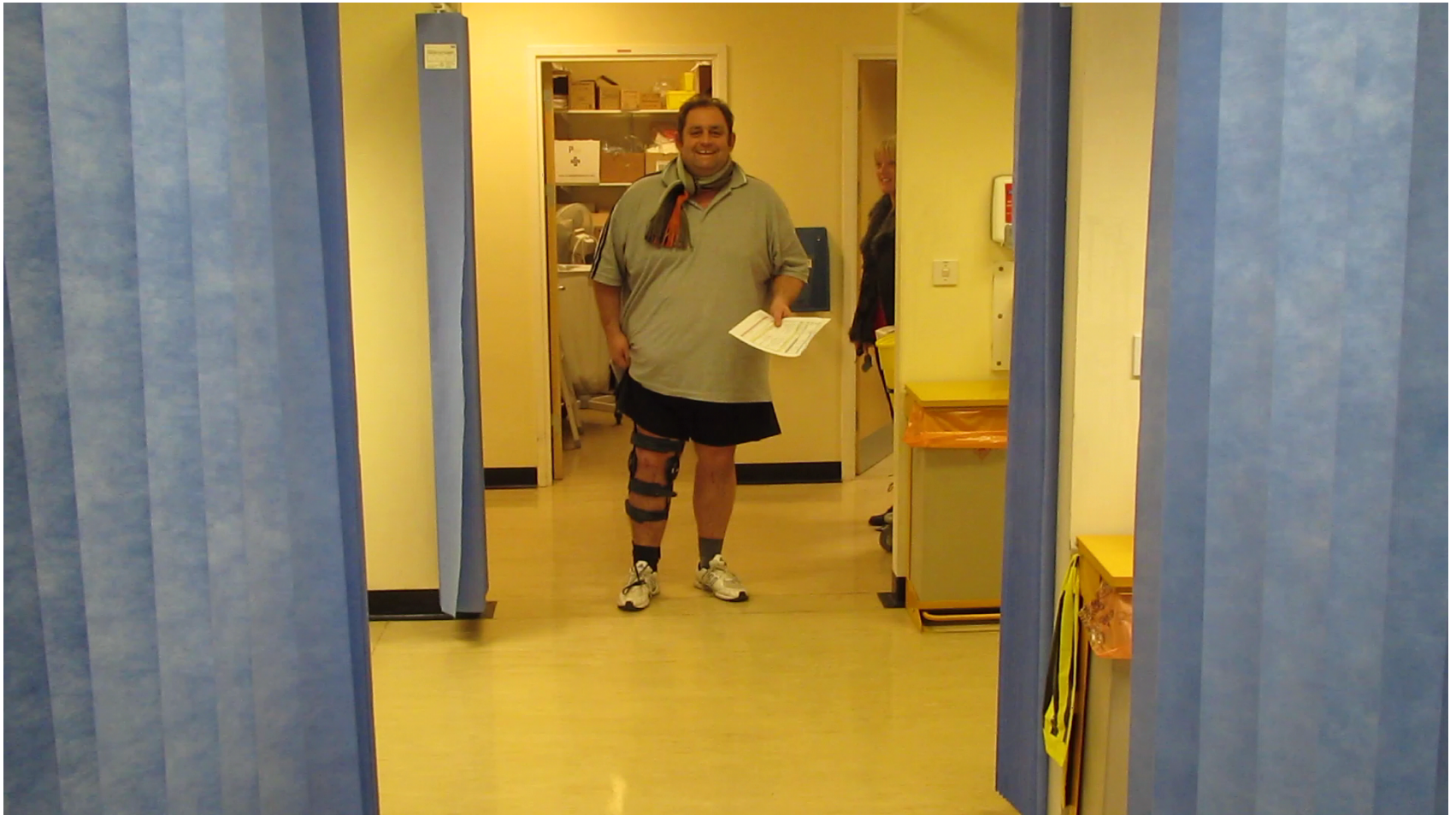

4
1
PHILIPS BV Libra

Post staged reconstruction

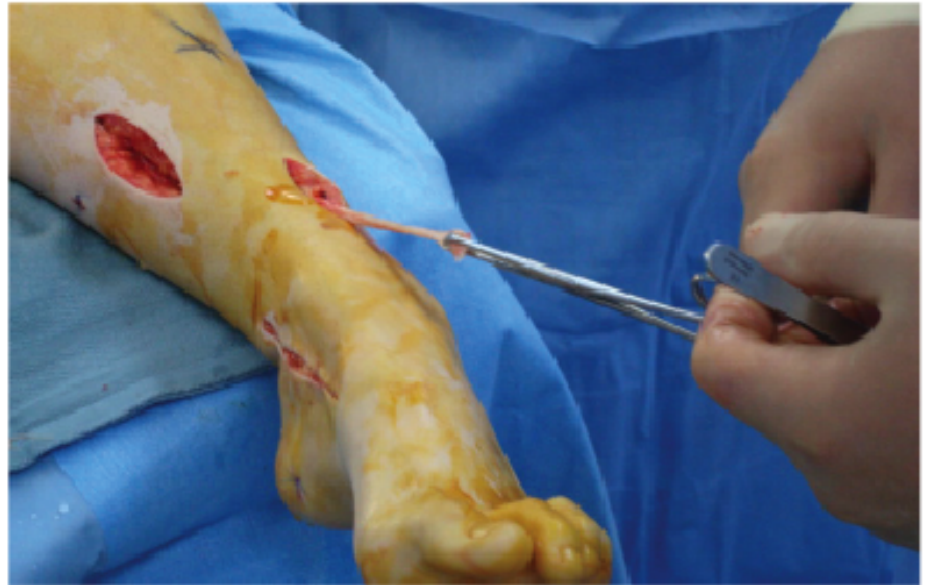

Return to clinic



Return to sport

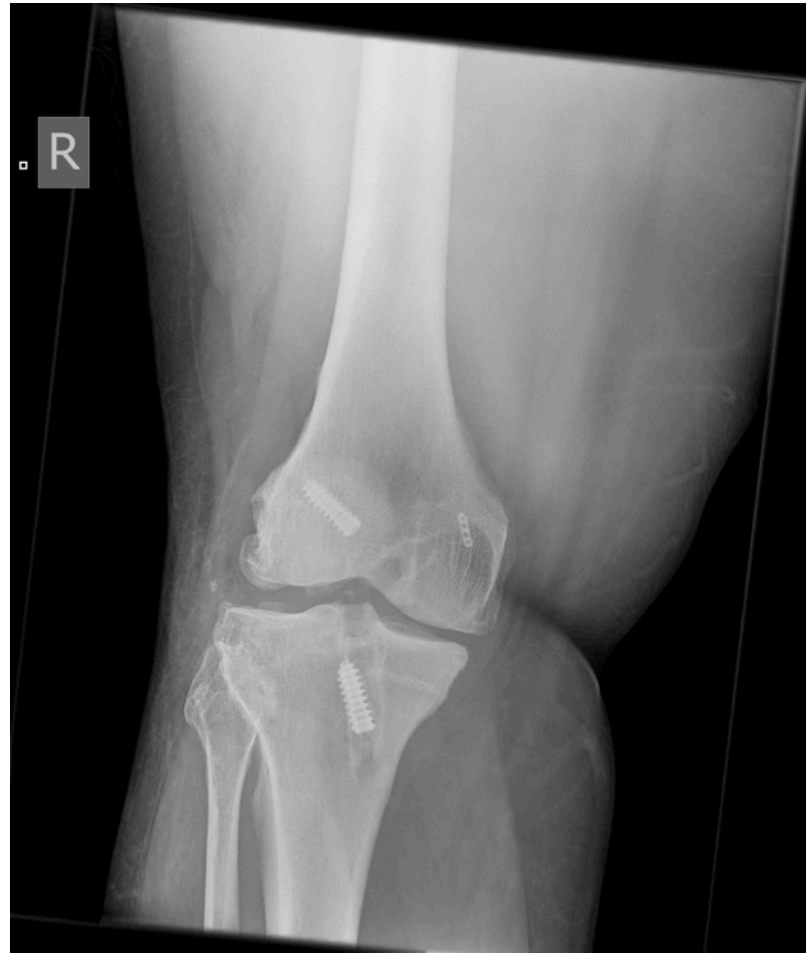- Squash with AFO
- Depression
- Struggled foot,
- No improvement 18 months
- Tibialis posterior transfer
 - Cast removed
 - Cries



Here one can see an intraoperative view of the transfer through the intraosseous membrane.

Now knee pain

- Injection
 - LA & Steroid
- Arthroscopy??
- Weight gain ++
- Bariatric surgery
- What to do??



18th ESSKA Congress

9 – 12 May 2018



Glasgow, Scotland, UK

www.esska-congress.org



ESSKA President
Romain Seil (Luxembourg)

Congress President
Jón Karlsson (Sweden)

Scientific Chairman
Gino M. Kerkhoffs (The Netherlands)
Fares S. Haddad (UK)
Michael T. Hirschmann (Switzerland))

Organiser & Contact
Intercongress GmbH
esska@intercongress.de



