Parc de Salut Barcelona

MAR

Clinical Case 1

Joan C. Monllau MD, PhD

- **Male, 20 y old**
- Water polo professional player (*CN At Barceloneta*)
- **Main complaint left Knee pain**

<u>Medical History</u>

- June 2011
  - Arthroscopic Drilling for *Osteochondritis Dissecans* medial femoral condyle left knee

- August 2014
  - Microfractures + BST Cargel (failure of previous treatment)

August 2014

MicroFx + BST CarGel

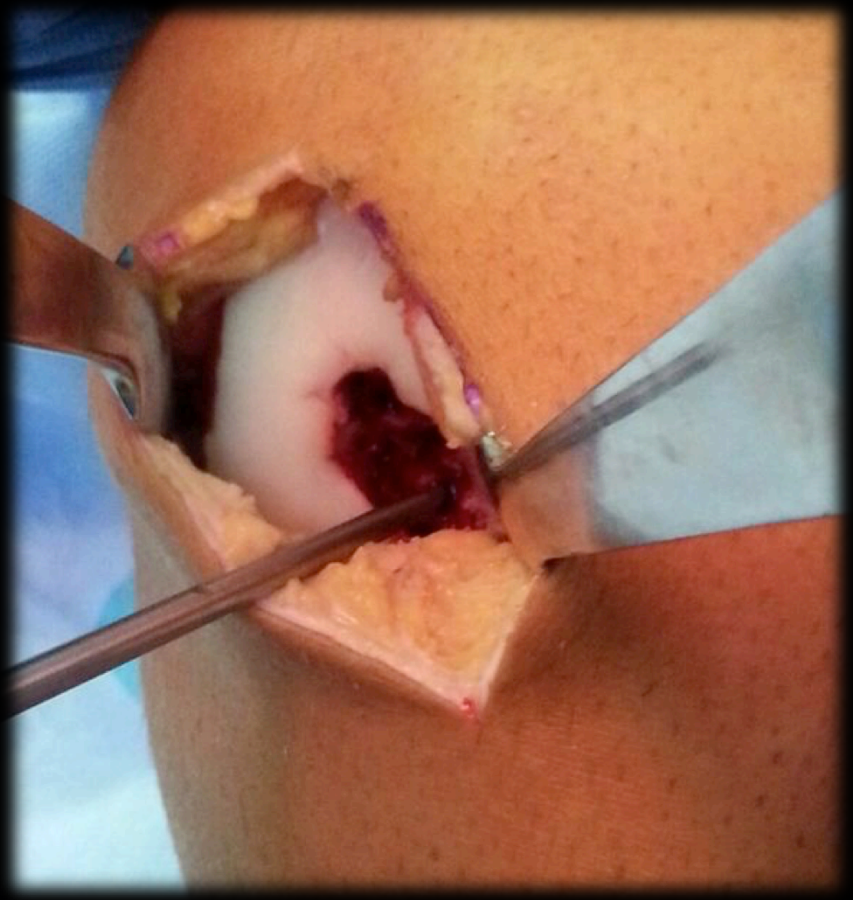

Main Complaint

- Long-lasting pain in the medial side of the left knee
- Impossible to run

Ph Exam

- 104kg / 197 cm
- General limb alignment in varus (particularly the involved side)
- Full ROM (0/0/140º)
- Knee stability
  - Lachman, pivot shift, ant & post drawer, VR-VL (-)
- Medial side pain and tenderness, no effusion, no locking, catching, etc

Imaging

- X-ray
- MRI
- CT Scan
- Some other

X-Ray

- assimetric varus malalignment (8º)
- patellar heitgh at limit (CD 1)

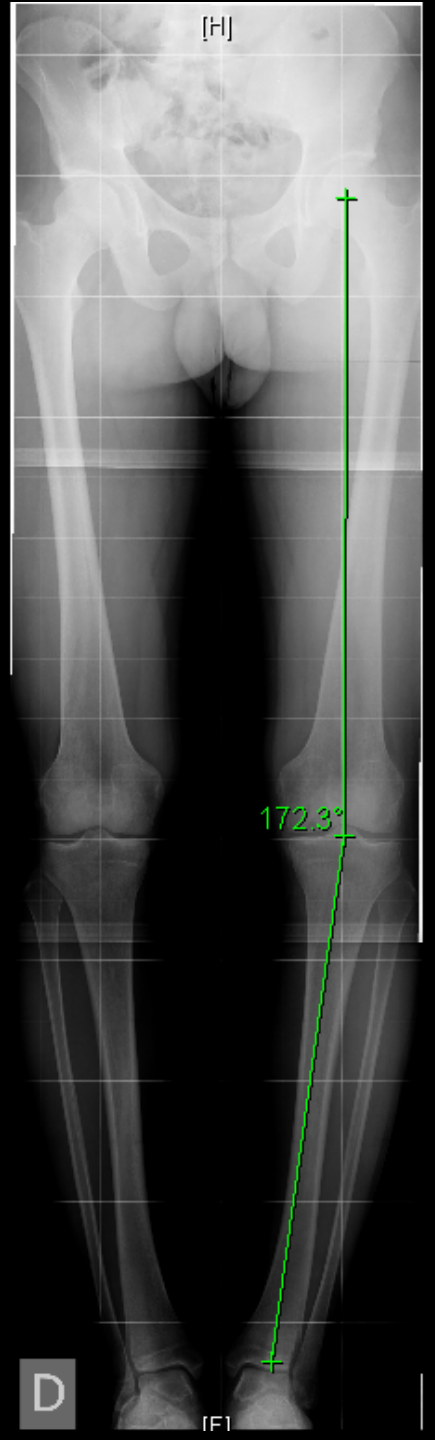

MRI

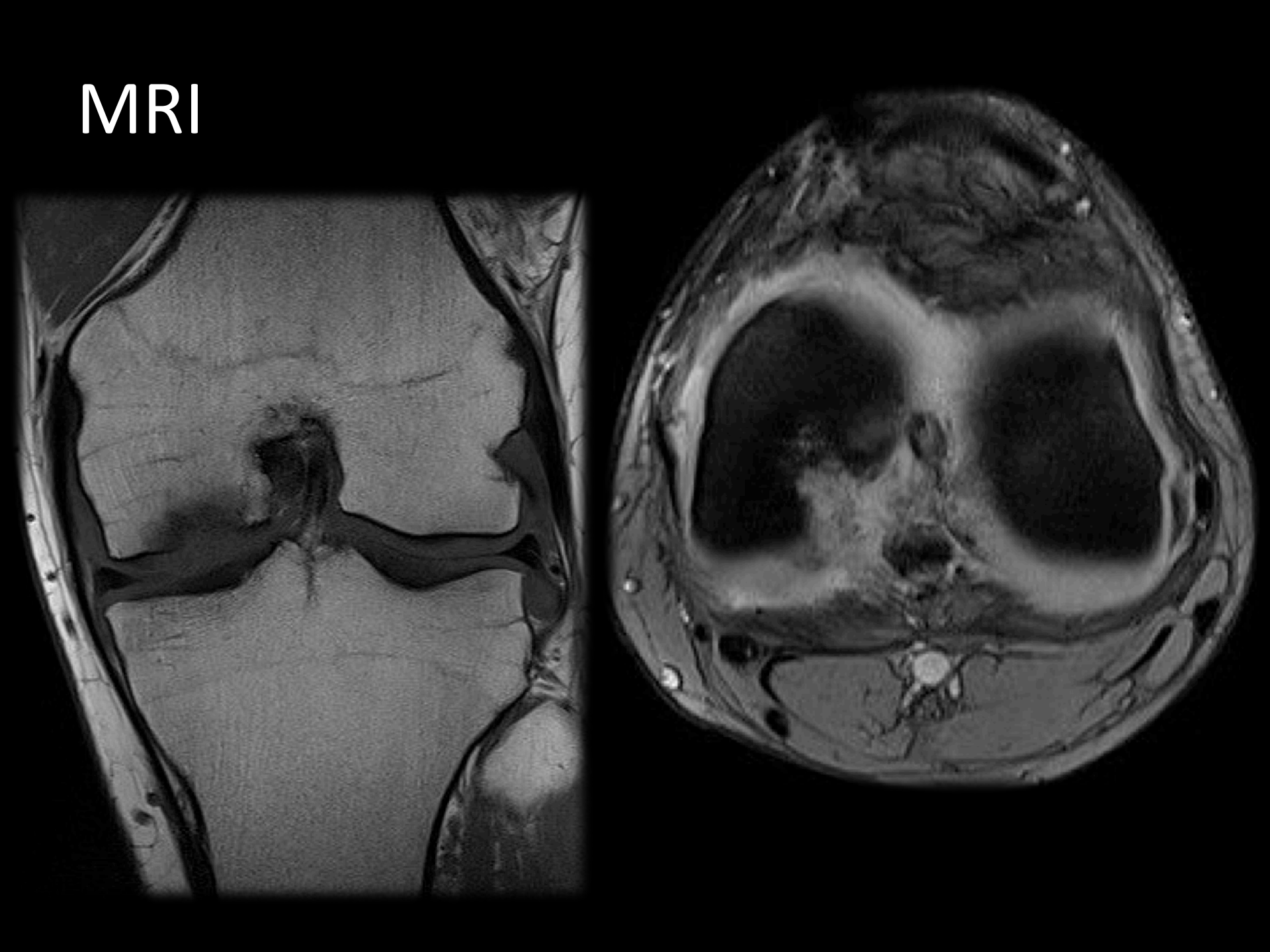

MRI

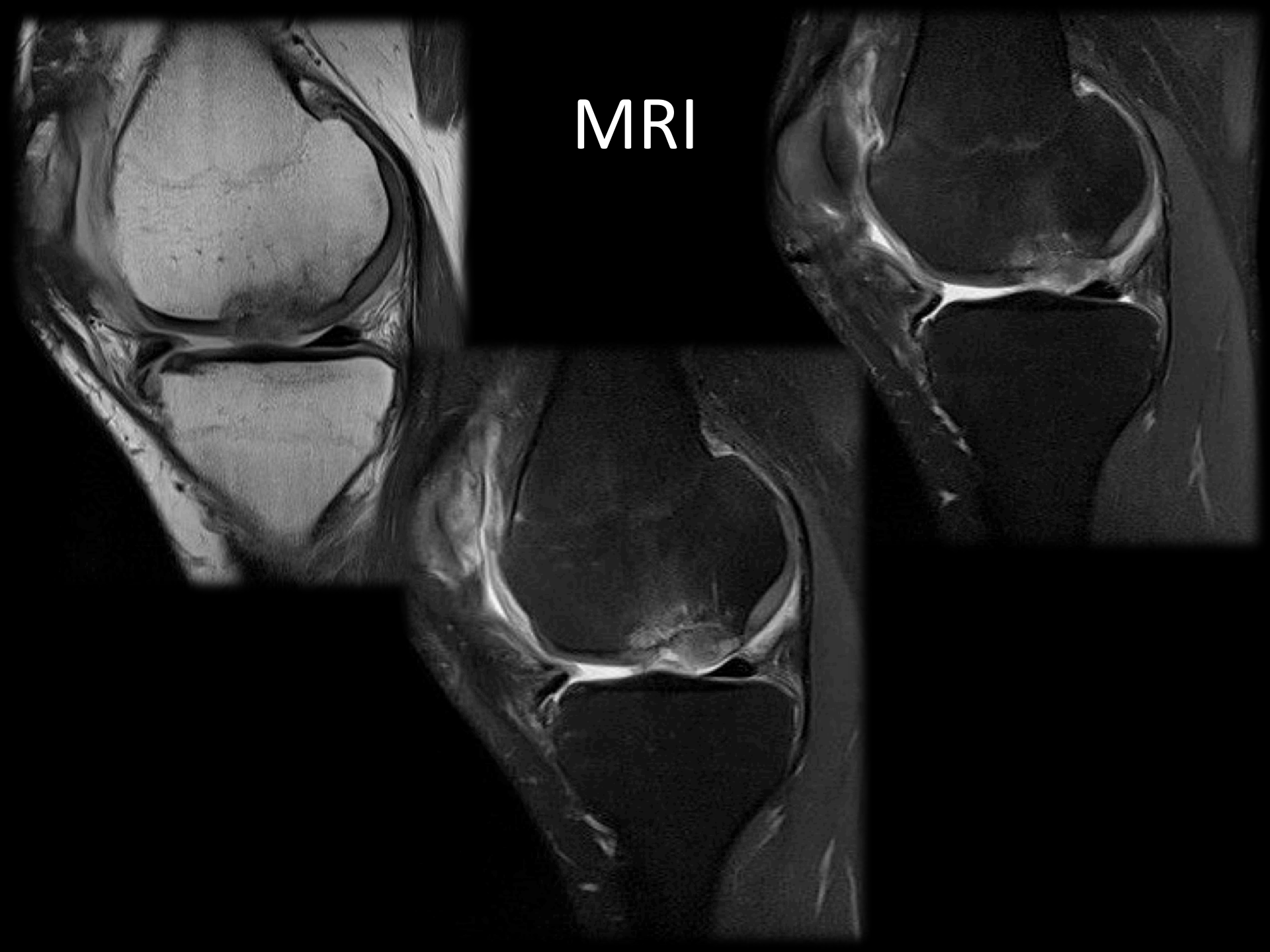

Diagnosis

- ✓ Symtomatic chondral injury (failed chondral repair) in MFC
- ✓ Genu-varum (8º) left limb (Fujisawa 12º)

Tx Options

1. Cartilage repair
2. HTO (biplanar open wedge)
3. Combined procedure
4. Some other surgical options (metal resurfacing, etc..)

Plan

- ✓ Mosaicplasty + HTO (biplanar open wedge)

Arthroscopy

January 2015

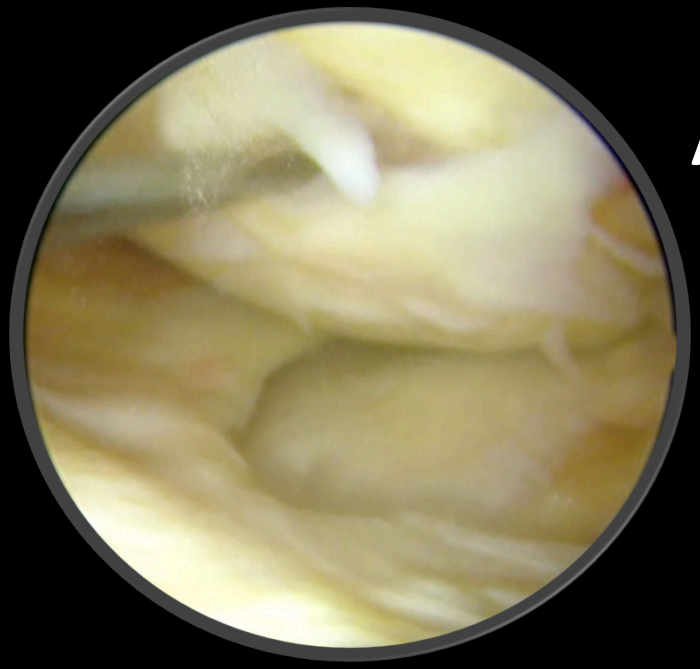

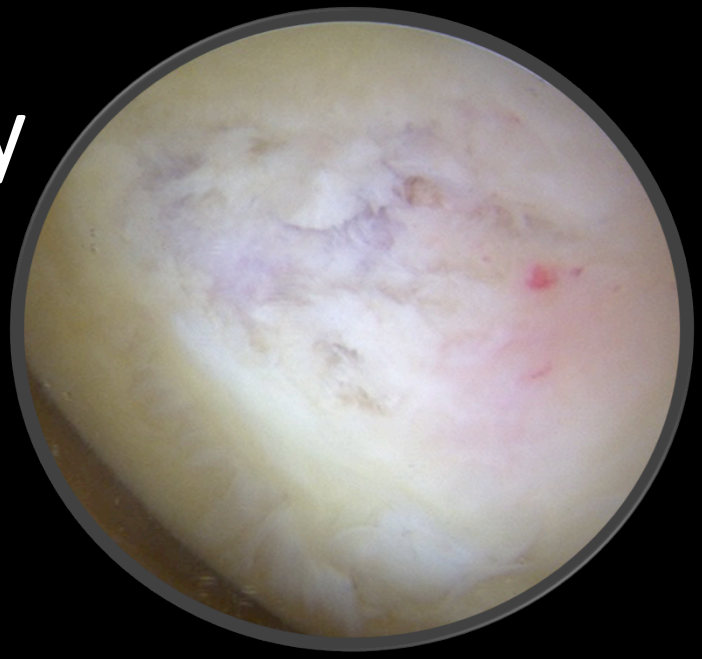

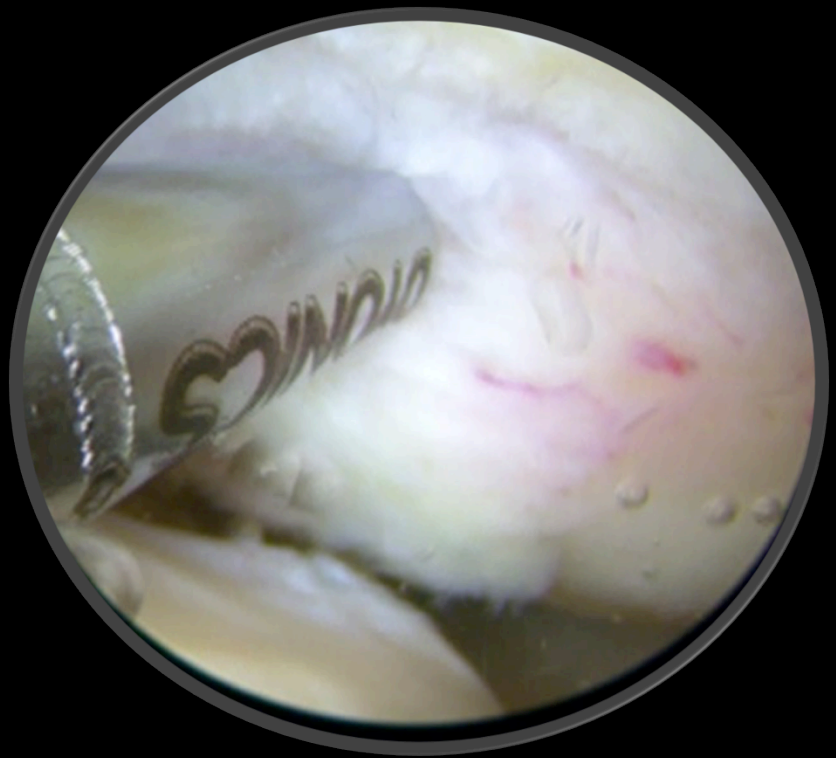

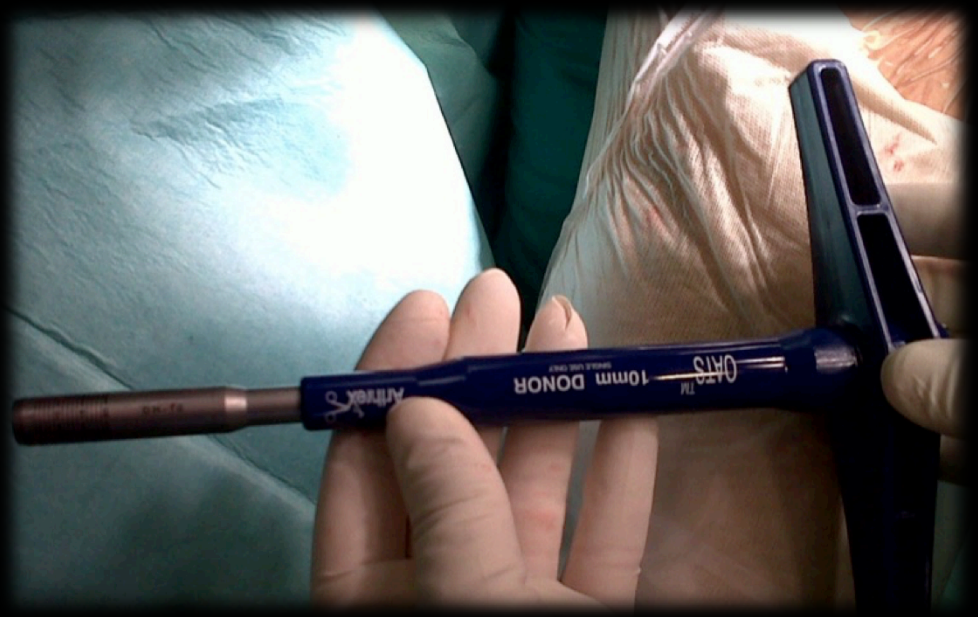

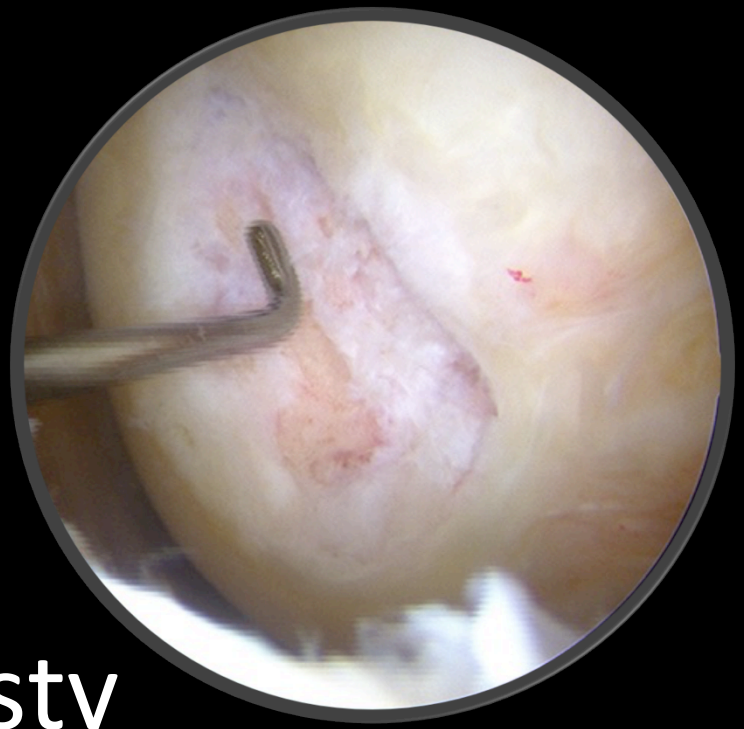

Mosaicplasty

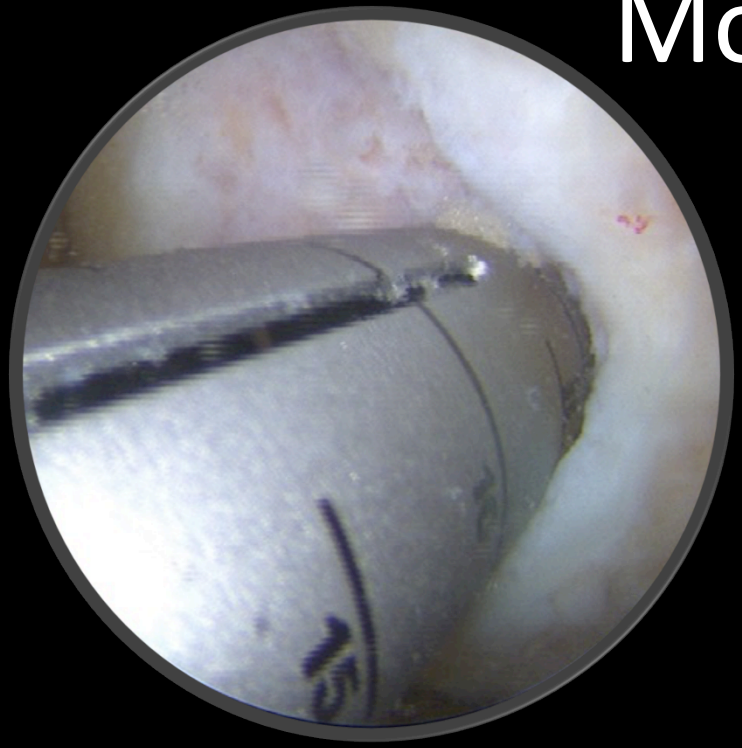

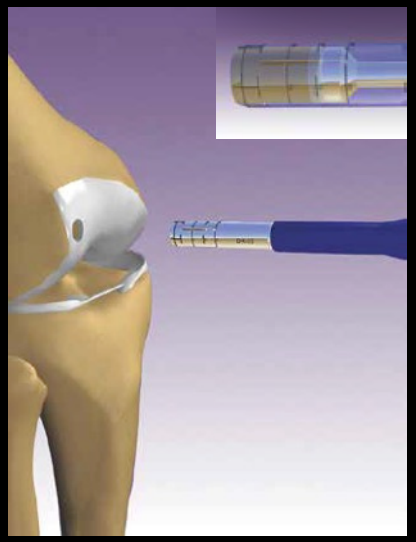

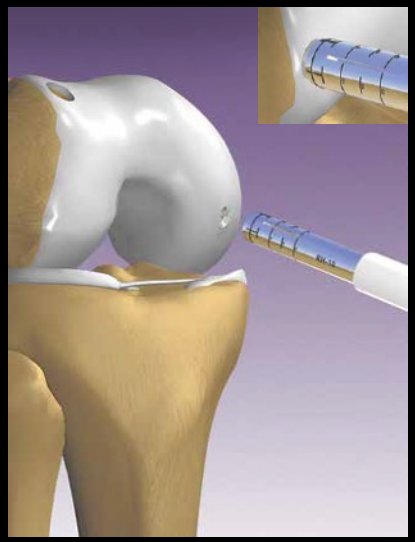



Mosaicplasty

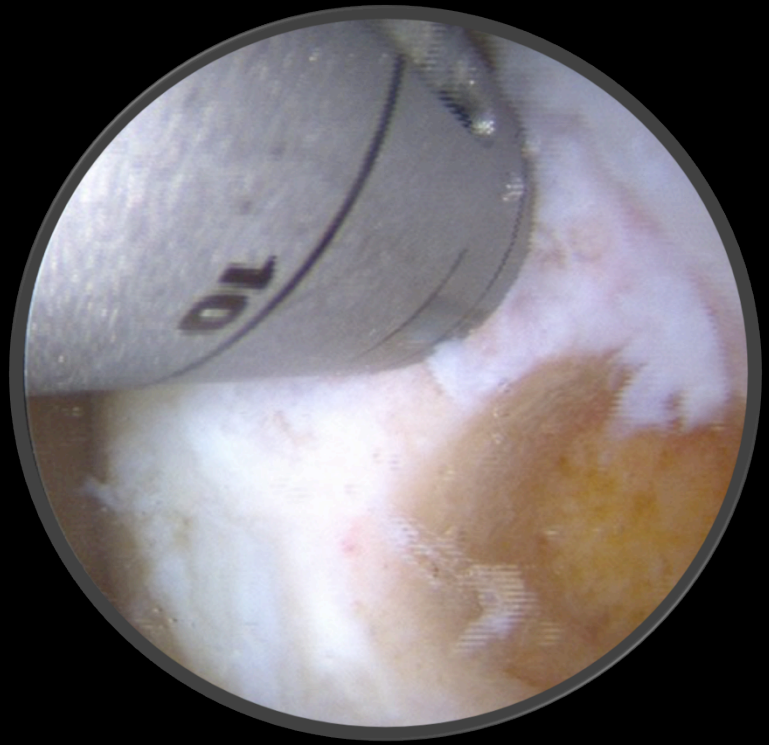

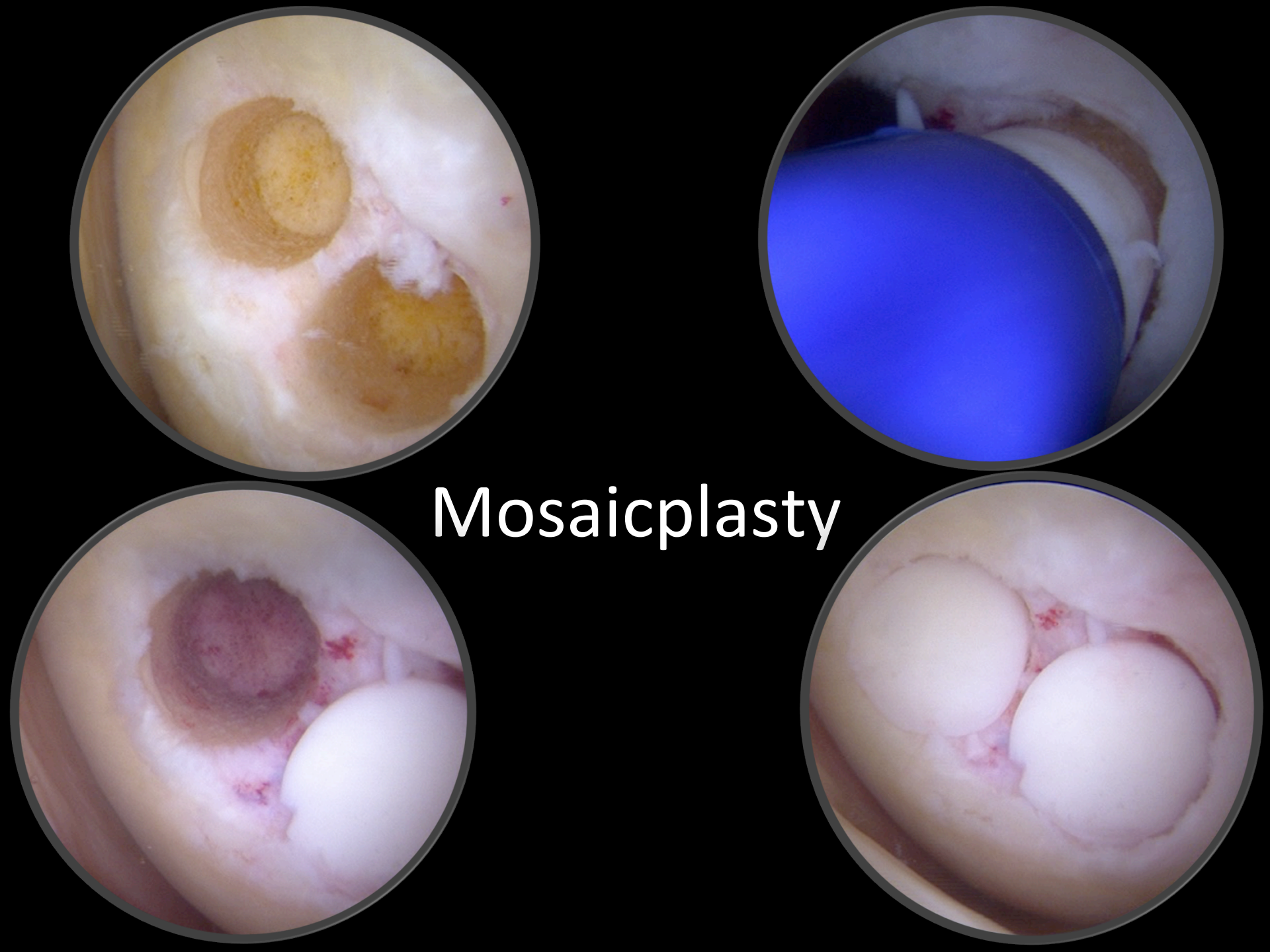
Mosaicplasty

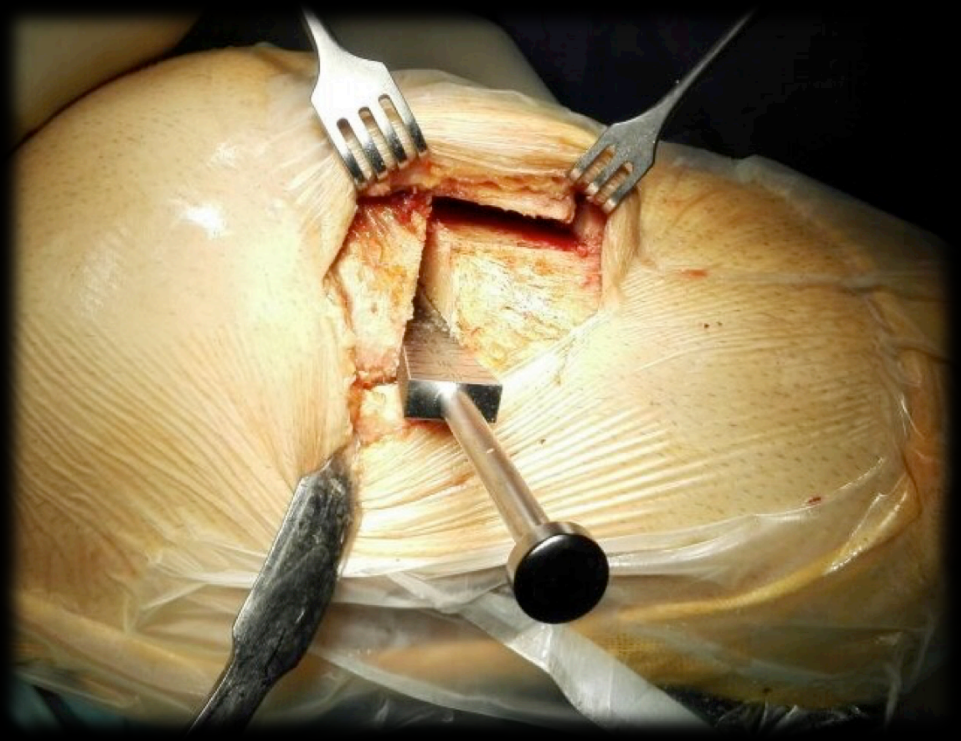

HTO biplanar OW

- Intended correction 12º (Fujisawa)
- L-Shaped cut down (to avoid patella lowering)

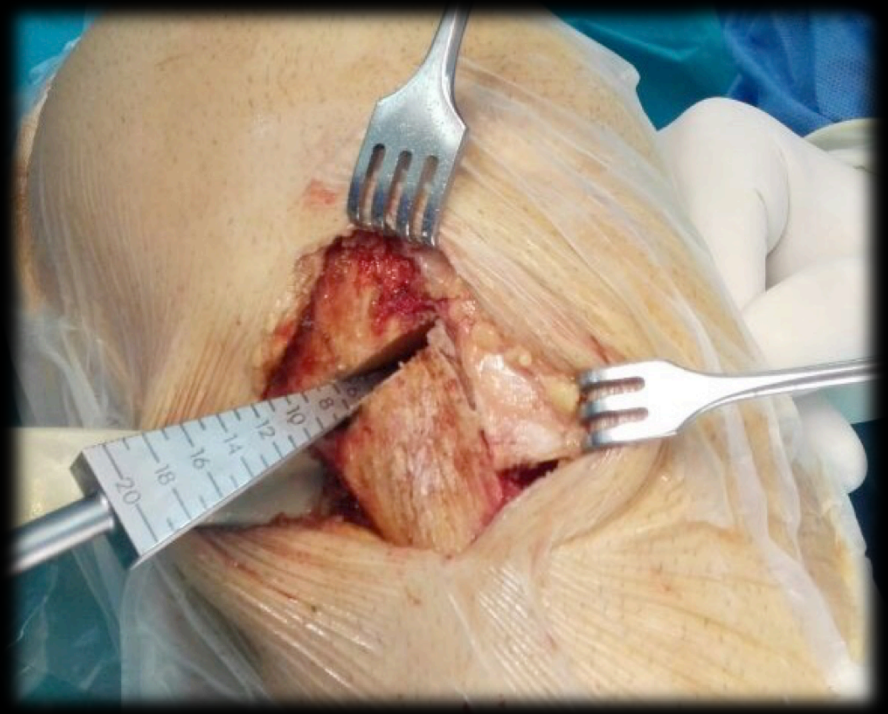

1 y FU

- Full recovery
- Back to sports

2016

Olimpic Games Rio 7th