

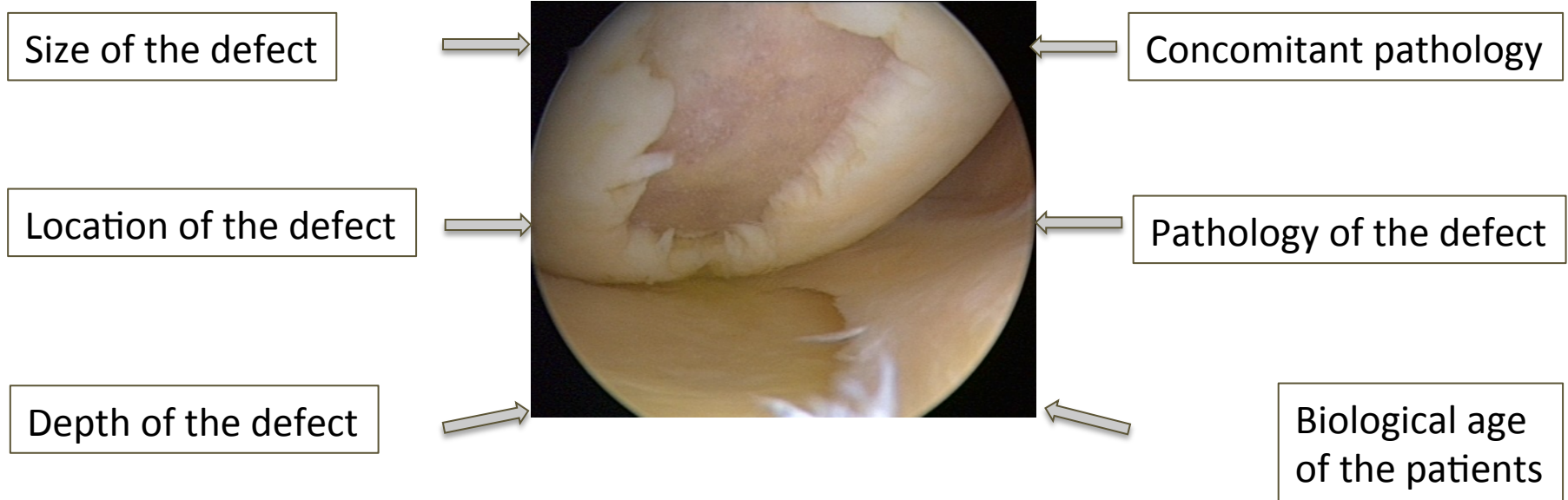

7TH Advanced Course on Knee Surgery 14th to 18th January 2018 Val d'Isère – France

Romain Seil, Roland Becker

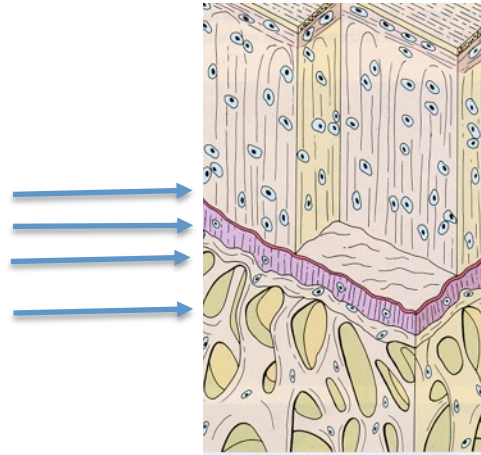
Classification of cartilage lesions

Important factors



Hyaline Cartilage

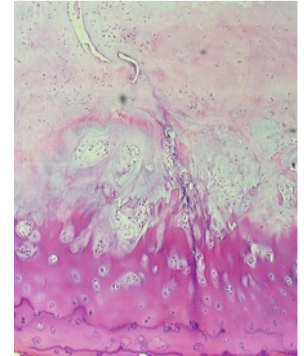
Tide mark
Calcified Cartilage
Subchondral Bone
Cancellous Bone



Superficial tangential zone (10-20%)

Middle zone (40-60%)

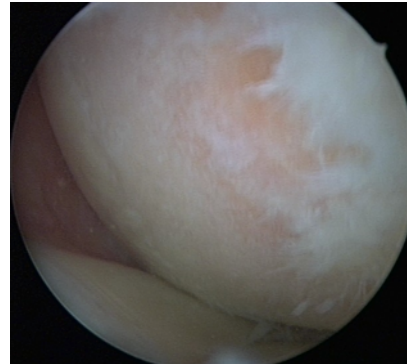
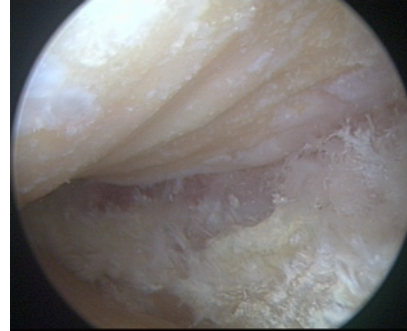
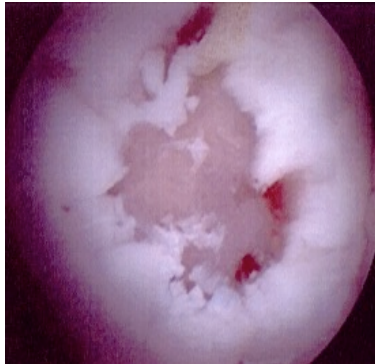
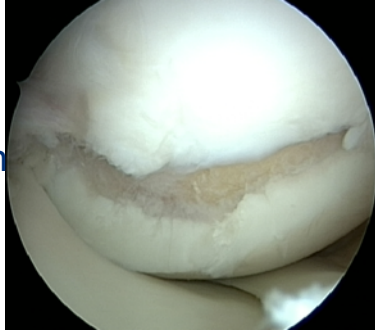Deep zone (30%)



- Mechanical protection (compression and shear forces)
- Cell organisation / - adhaesion
- Cell communication
- Cell activity
- Cell proliferation / - differentiation

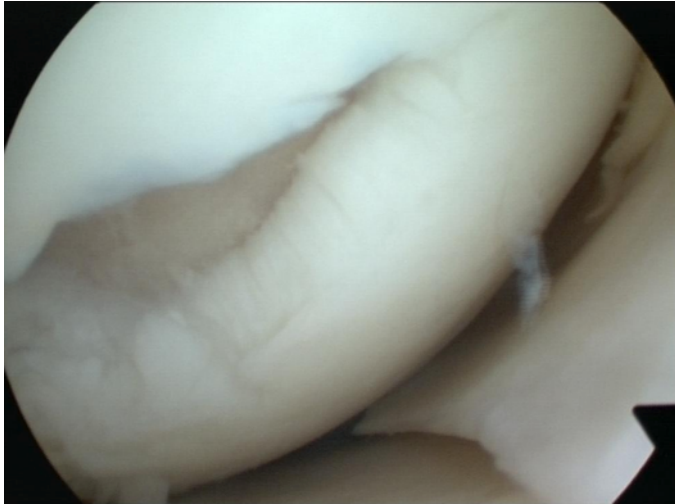
TRAUMATIC versus DEGENERATIVE cartilage lesions

- Well defined defect
- True boarder of the lesion
- Smaller in size
- Good bone quality and bleeding

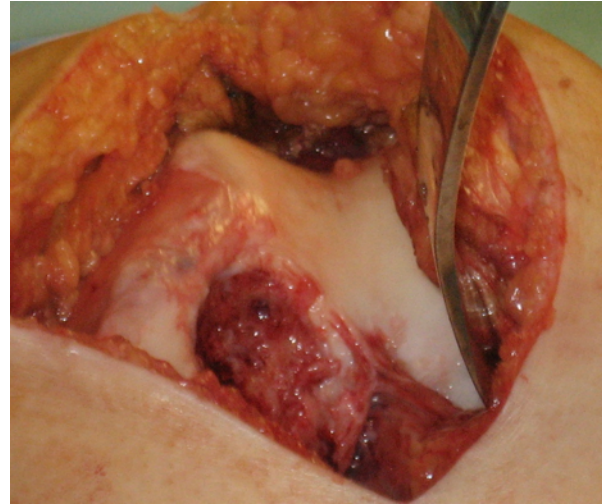


- Not well defined defect
- Sclerotic bone
- No true edge of the lesion
- Entire weight bearing area affected

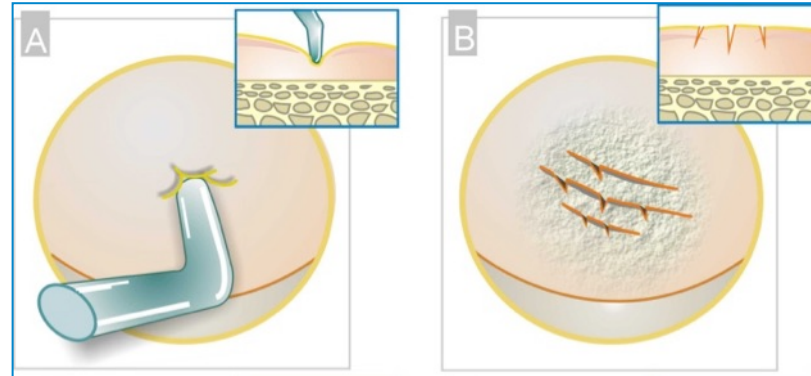
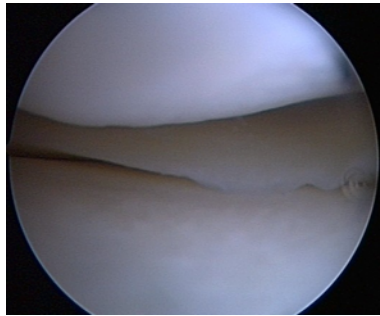
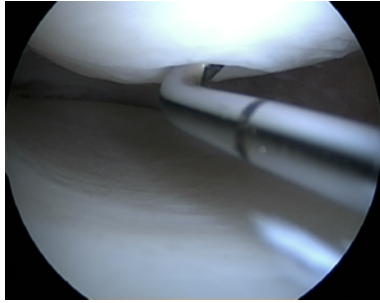
Chondral defect



Osteochondral defect (common in OD)



Outerbridge Classification

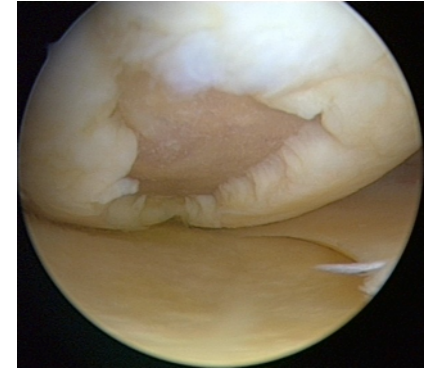
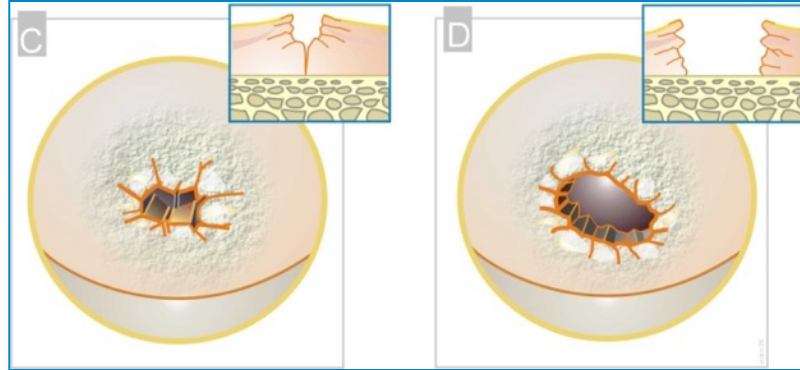
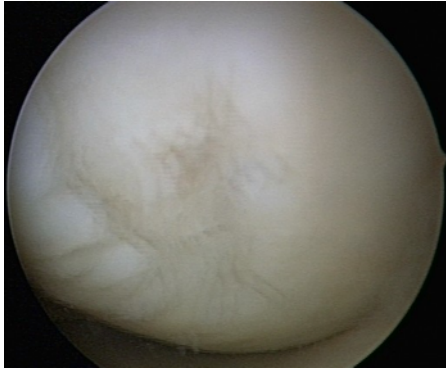

Grade 0 : no cartilage damage

Grade 1: Swelling and softening

Grade 2: less than 50% loss of cartilage thickness

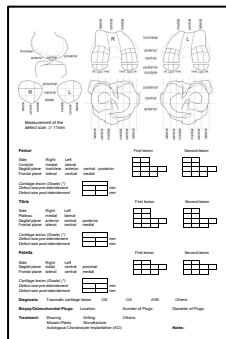
Outerbridge Classification



Grade 3: Loss of cartilage thickness of $>50\%$

Grade 4: Complete loss of cartilage, subchondral bone
exposed

CARTRIDGE REPAIR ASSESSMENT			
Criteria	Points		
Region of Interest Repair	<ul style="list-style-type: none"> 1-5 mm with surrounding cartilage 1-5 mm with surrounding meniscus 1-5 mm repair cartilage surface 1-5 mm repair meniscus surface 	4	
Prosthetic 3"	<ul style="list-style-type: none"> 1-5 mm of cartilage of tibial surface 1-5 mm of cartilage of femoral surface 1-5 mm of meniscus of tibial surface 1-5 mm of meniscus of femoral surface 	4	
Integration to Host site	<ul style="list-style-type: none"> 1-5 mm of cartilage of tibial surface 1-5 mm of cartilage of femoral surface 1-5 mm of meniscus of tibial surface 1-5 mm of meniscus of femoral surface 	4	
Microscopic Appearance	<ul style="list-style-type: none"> 1-5 mm of cartilage of tibial surface 1-5 mm of cartilage of femoral surface 1-5 mm of meniscus of tibial surface 1-5 mm of meniscus of femoral surface 	4	
Overall Repair Assessment	<ul style="list-style-type: none"> Score 1 Score 2 Score 3 Score 4 Score 5 	10	4
Cartridge Repair	Location		
<p>(A) Prosthetic A:</p> <p>1-5 mm of cartilage of tibial surface</p> <p>1-5 mm of cartilage of femoral surface</p> <p>1-5 mm of meniscus of tibial surface</p> <p>1-5 mm of meniscus of femoral surface</p>	<p>(B) Prosthetic B:</p> <p>1-5 mm of cartilage of tibial surface</p> <p>1-5 mm of cartilage of femoral surface</p> <p>1-5 mm of meniscus of tibial surface</p> <p>1-5 mm of meniscus of femoral surface</p>		

[illegible]

Consists of two parts:

A: PATIENT PART:
ICRS Injury questionnaire
The IKDC Subjective Knee Evaluation Form-2000

B: SURGEONS PART
ICRS Knee Surgery History Registration
IKDC Knee Examination form-2000
ICRS- Articular cartilage injury mapping system
ICRS-Articular cartilage injury classification
ICRS-Osteochondritis dissecans classification
ICRS-Cartilage Repair Assessment system

The ICRS Clinical Cartilage Injury Evaluation system-2000 was developed during ICRS 2000 Standards Workshop at Schloss Münchenwiler, Switzerland, January 27-30, 2000 and further discussed during the 3rd ICRS Meeting in Göteborg, Sweden, Friday April 28, 2000. The participants in the Clinical Münchenwiler Evaluation Group were as follows:

Chairman Mats Brittberg, Sweden
Paolo Aglietti, Italy
Ralph Gambardella, USA
Laszlo Hangody, Hungary
Hans Jörg Hauselmann, Switzerland
Roland P Jakob, Switzerland
David Levine, USA
Stefan Lohmander, Sweden
Bert R Mandelbaum, USA
Lars Peterson, Sweden
Hans-Ulrich Staubli, Switzerland

There was a discussion regarding the use of IKDC-1999 vs KOOS (Knee Injury and Osteoarthritis Outcome Score). The decision in Göteborg was to continue with IKDC (IKDC representatives: A. Anderson, R. Jakob, H.-U. Stäubli) but there will also be comparative studies with the KOOS (<http://www.koos.nu/>)

The clinical evaluation system can also be combined with the ICRS Imaging Protocol as well as the ICRS Biomechanical Protocol

Comments on the ICRS Cartilage Evaluation forms to: mats.brittberg@telia.com

[illegible]

IKDC CURRENT HEALTH ASSESSMENT FORM *

Participant's Name _____

Your Full Name _____

Date of Birth _____

Today's Date _____

In general, would you rate your health as:

☐ Excellent ☐ Very Good

☐ Good ☐ Fair

☐ Poor

Compared to one year ago, how would you rate your health in general now?

☐ Much better than 1 year ago ☐ Somewhat better than 1 year ago

☐ About the same as 1 year ago ☐ Somewhat worse than 1 year ago

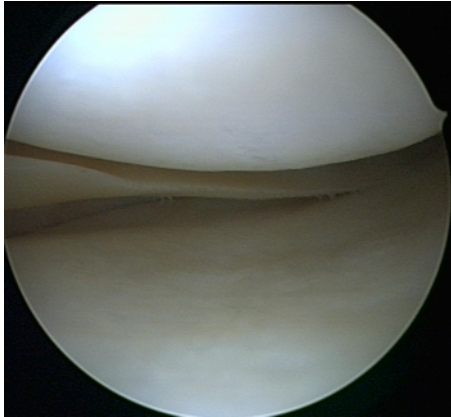
☐ Much worse than 1 year ago

Do you have any health conditions you might be taking a typical diet. Have your health care provider discussed this with you?

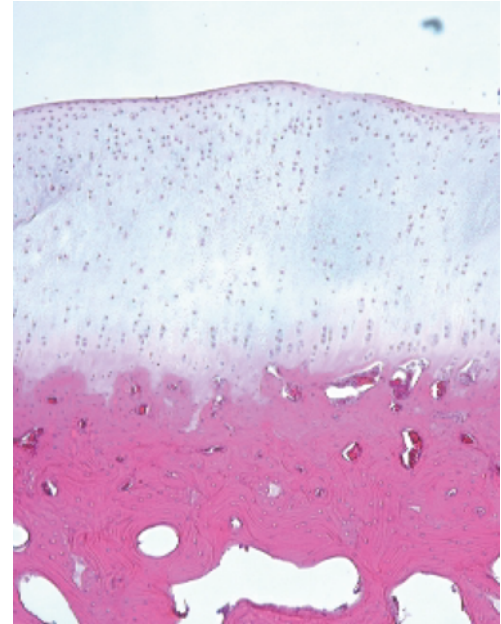
	Yes	No	Other	Not Used
* Significant arthritis, back or neck pain, lifting heavy objects, occupational or recreational injury.	<input type="checkbox"/>	<input type="checkbox"/>	<input type="checkbox"/>	<input type="checkbox"/>
* Diabetes	<input type="checkbox"/>	<input type="checkbox"/>	<input type="checkbox"/>	<input type="checkbox"/>
* High blood pressure	<input type="checkbox"/>	<input type="checkbox"/>	<input type="checkbox"/>	<input type="checkbox"/>
* Existing severe joint or bone disease	<input type="checkbox"/>	<input type="checkbox"/>	<input type="checkbox"/>	<input type="checkbox"/>
* Existing severe heart or lung disease	<input type="checkbox"/>	<input type="checkbox"/>	<input type="checkbox"/>	<input type="checkbox"/>
* Existing weakness or swelling	<input type="checkbox"/>	<input type="checkbox"/>	<input type="checkbox"/>	<input type="checkbox"/>
* Existing nerve disease	<input type="checkbox"/>	<input type="checkbox"/>	<input type="checkbox"/>	<input type="checkbox"/>
* Existing severe blood disorders	<input type="checkbox"/>	<input type="checkbox"/>	<input type="checkbox"/>	<input type="checkbox"/>
* Existing eye disease	<input type="checkbox"/>	<input type="checkbox"/>	<input type="checkbox"/>	<input type="checkbox"/>
* Existing or growing psoriasis	<input type="checkbox"/>	<input type="checkbox"/>	<input type="checkbox"/>	<input type="checkbox"/>

[illegible]

Smooth shiny surface
Some swelling

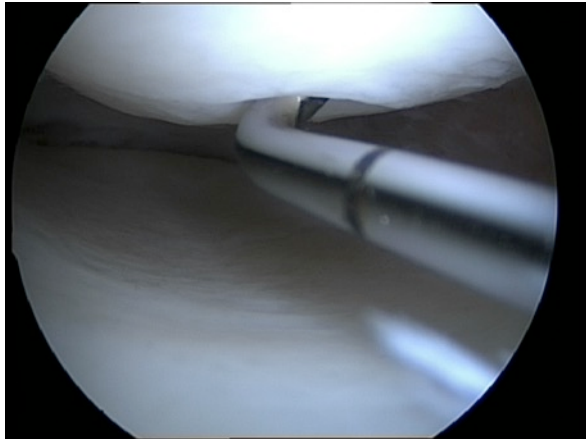


ICRS Grade 0 - Normal




ICRS Grade 1 – Nearly Normal

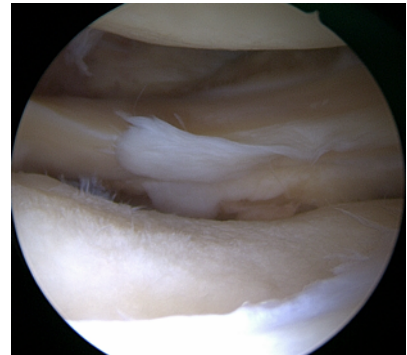
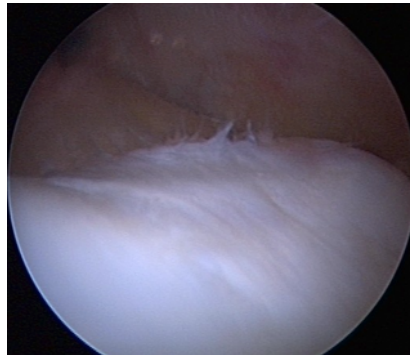
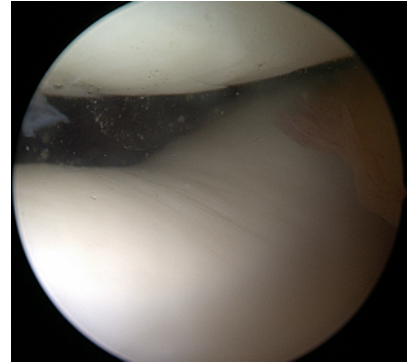
Superficial lesions. Soft indentation (A) and/or superficial fissures and cracks (B)



A


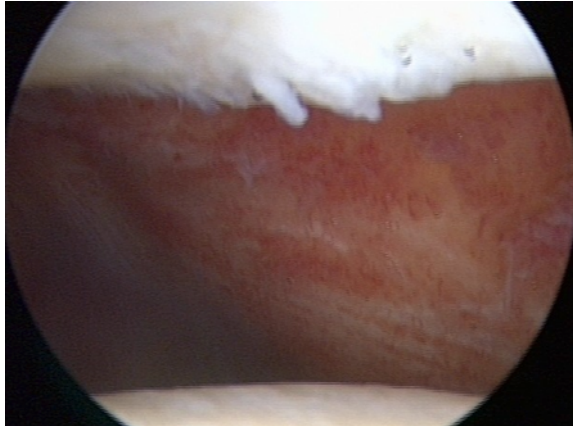


B



ICRS Grade 2 – Abnormal

Lesions extending down to <50% of cartilage depth


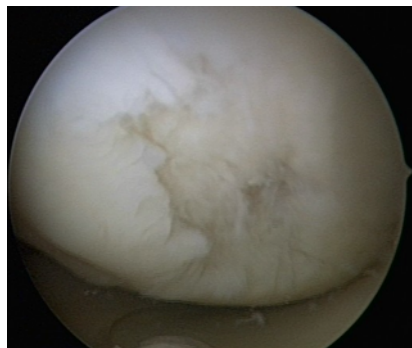


Cave:


Difficult to assess with the hook

ICRS Grade 3 – Severely Abnormal


Cartilage defects extending down >50% of cartilage depth (A) as well as down to calcified layer (B) and down to but not through the subchondral bone (C). Blisters are included in this Grade (D)




A



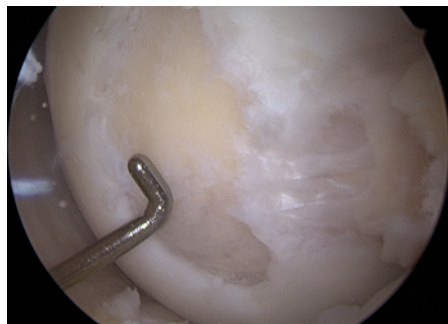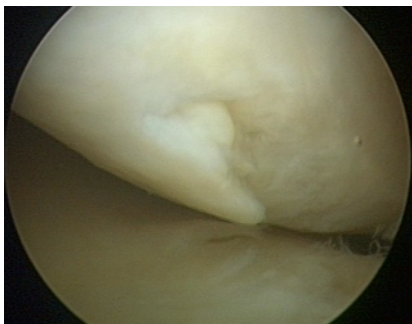
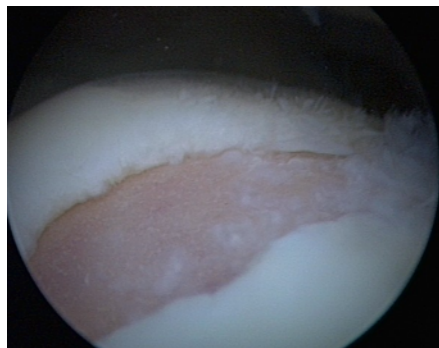
B




C



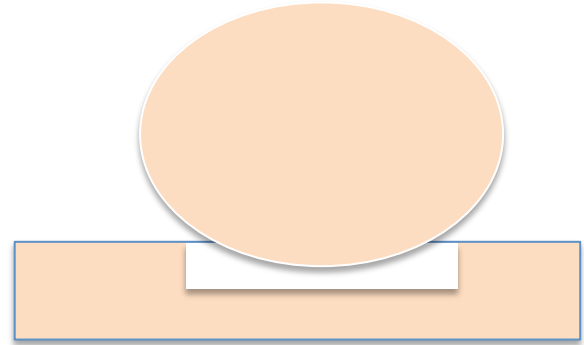
D



Containment of the defect

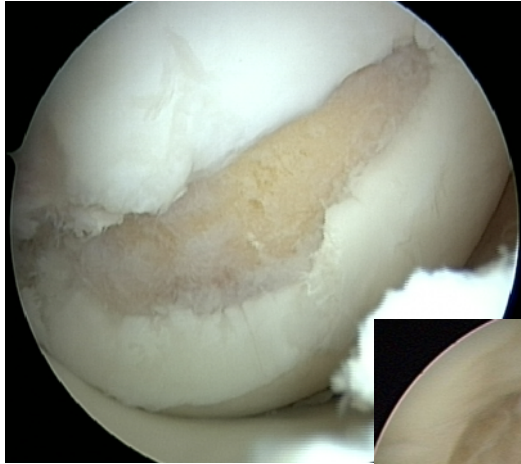


- Containment of the defect
- Stable edges of the defect required



No containment of the defect

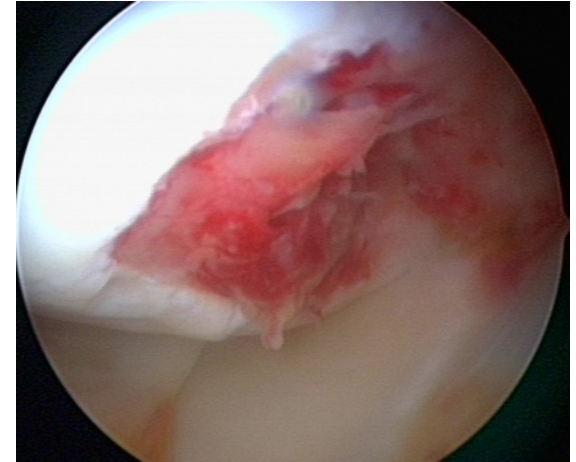
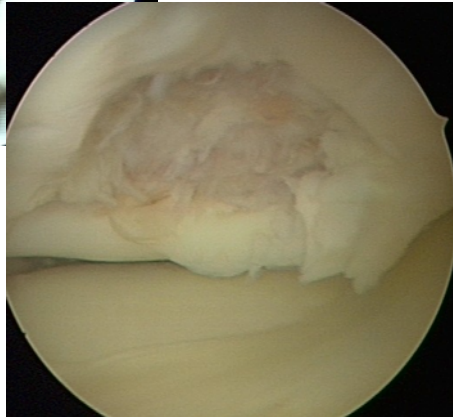
ICRS Grade 4 – Severely Abnormal



A



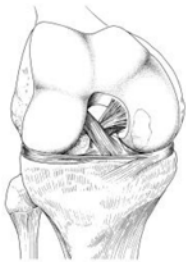
B



- Penetration into the subchondral and cancellous bone

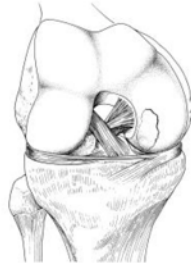Osteochondral Lesions

ICRS OCD I



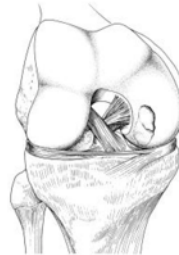Stable, continuity: Softened area covered by intact cartilage.

ICRS OCD II



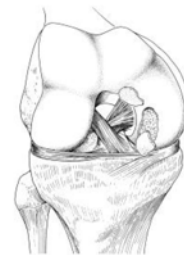Partial discontinuity, stable on probing

ICRS OCD III

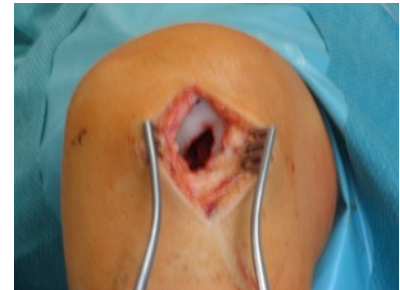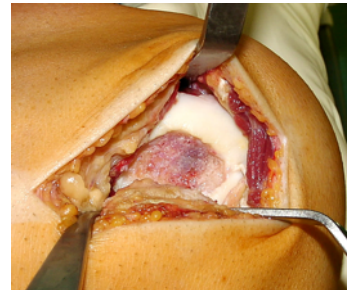
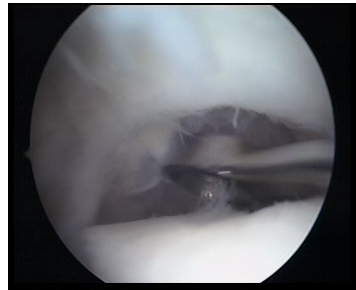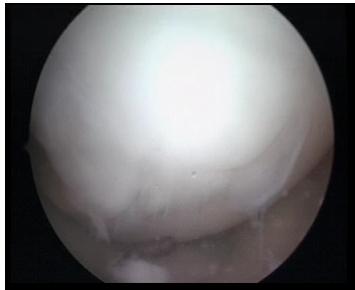


Complete discontinuity, "dead in situ", not dislocated.

ICRS OCD IV



Dislocated fragment, loose within the bed or empty defect. > 10mm in depth is B-subgroup



MRI – Score for cartilage defects

WORMS: Whole-Organ Magnetic Resonance Score

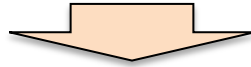
BLOKS: Boston-Leeds Osteoarthritis Knee Score

MRI – Score for cartilage defects

WORMS: Whole-Organ Magnetic Resonance Score

BLOKS: Boston-Leeds Osteoarthritis Knee Score

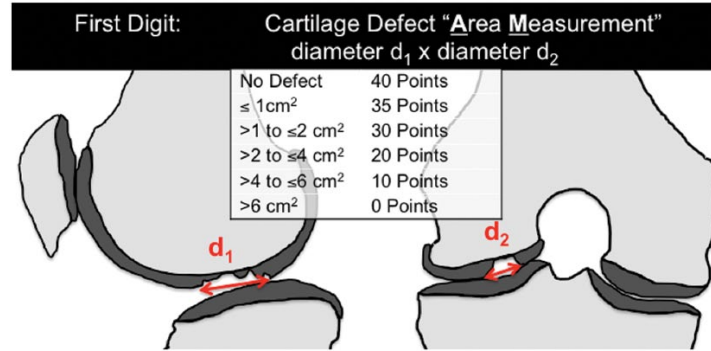
Scores rather designed for Osteoarthritis than for cartilage defects



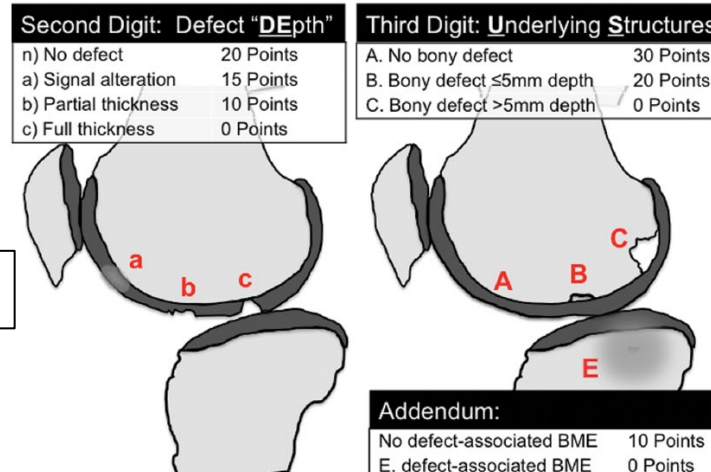
AMADEUS: Area Measurement And DEpth & Underlying Structures

AMADEUS

Size of the defect



Depth of the defect



Subchondral bone

Summary

- **Identify carefully the cartilage lesion**
- **Look at the size, depth and subchondral bone**
- **Consider the biological age the patients**
- **Consider concomitant pathologies**