# Popliteal cysts

**Philippe Landreau, MD**
Consultant Orthopedic Surgeon
Shoulder, Knee and Sports Surgery
Orthocure & Mediclinic
Dubai
UAE

# Popliteal cysts, or Baker’s cysts

- Fluid-filled sacs in the popliteal fossa, often secondary to intra-articular knee disorders.

- William Morant Baker (1877): 8 cases

Baker WM. On the formation of synovial cysts in the leg in connection with disease of the knee joint. 1877. Clin Orthop Relat Res. 1994;299:2-10.

# Incidence

- Frequent
- 38% of MRI performed in symptomatic knee.

Sansone V, De Ponti A, Minio Paluello G, Del Maschio A. Popliteal cysts and associated disorders of the knee: critical review with MR imaging. Int Orthop. 1995;19:275-279.

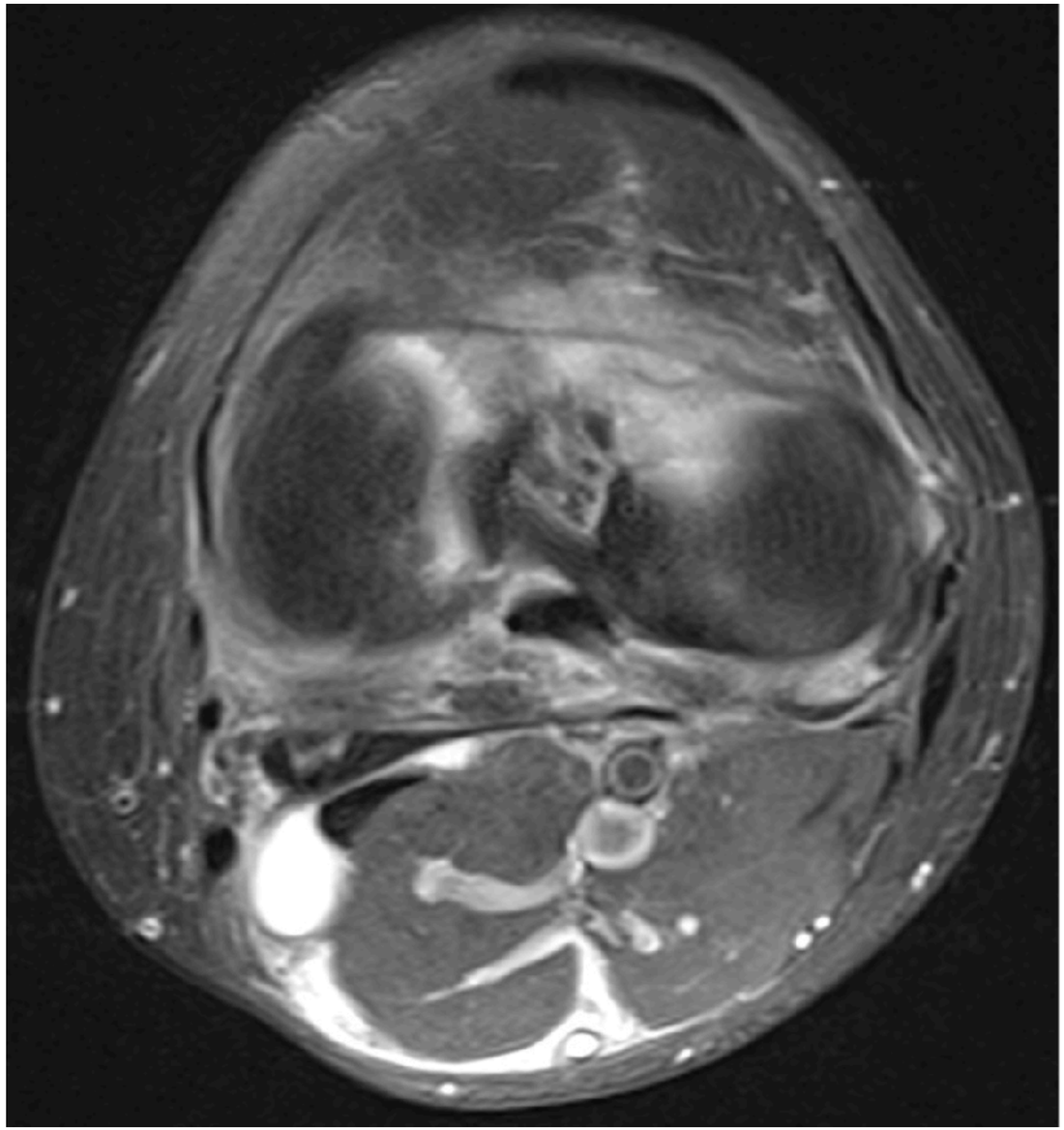

# Pathoanatomy

- Originates from the gastrocnemius-semimembranosus bursa (Bursa located between the medial head of the gastrocnemius and semimembranosus).

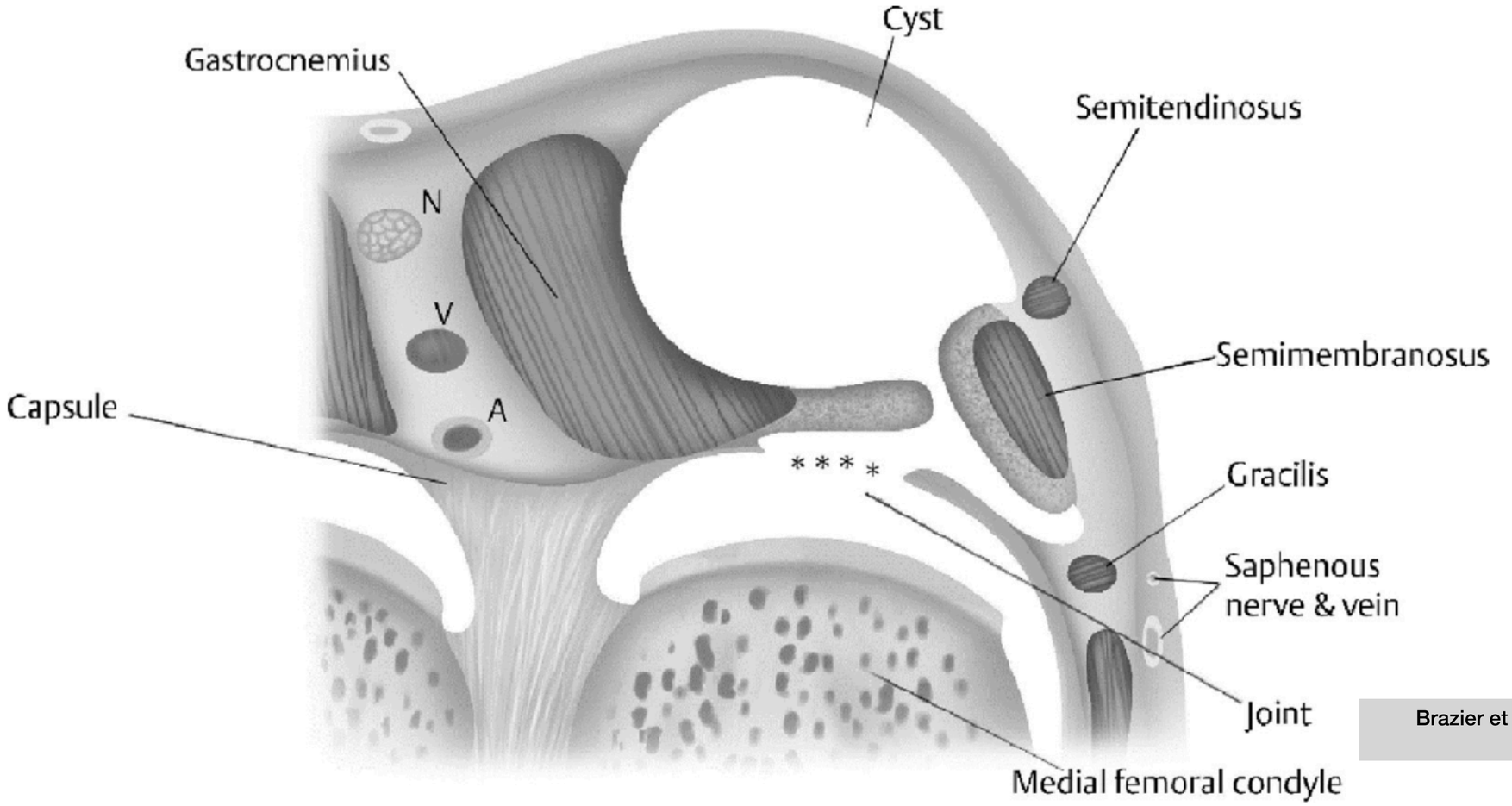


**Medial**

Brazier et al. Arthroscopic Treatment of Popliteal Cysts. Arthroscopy Techniques. 2018

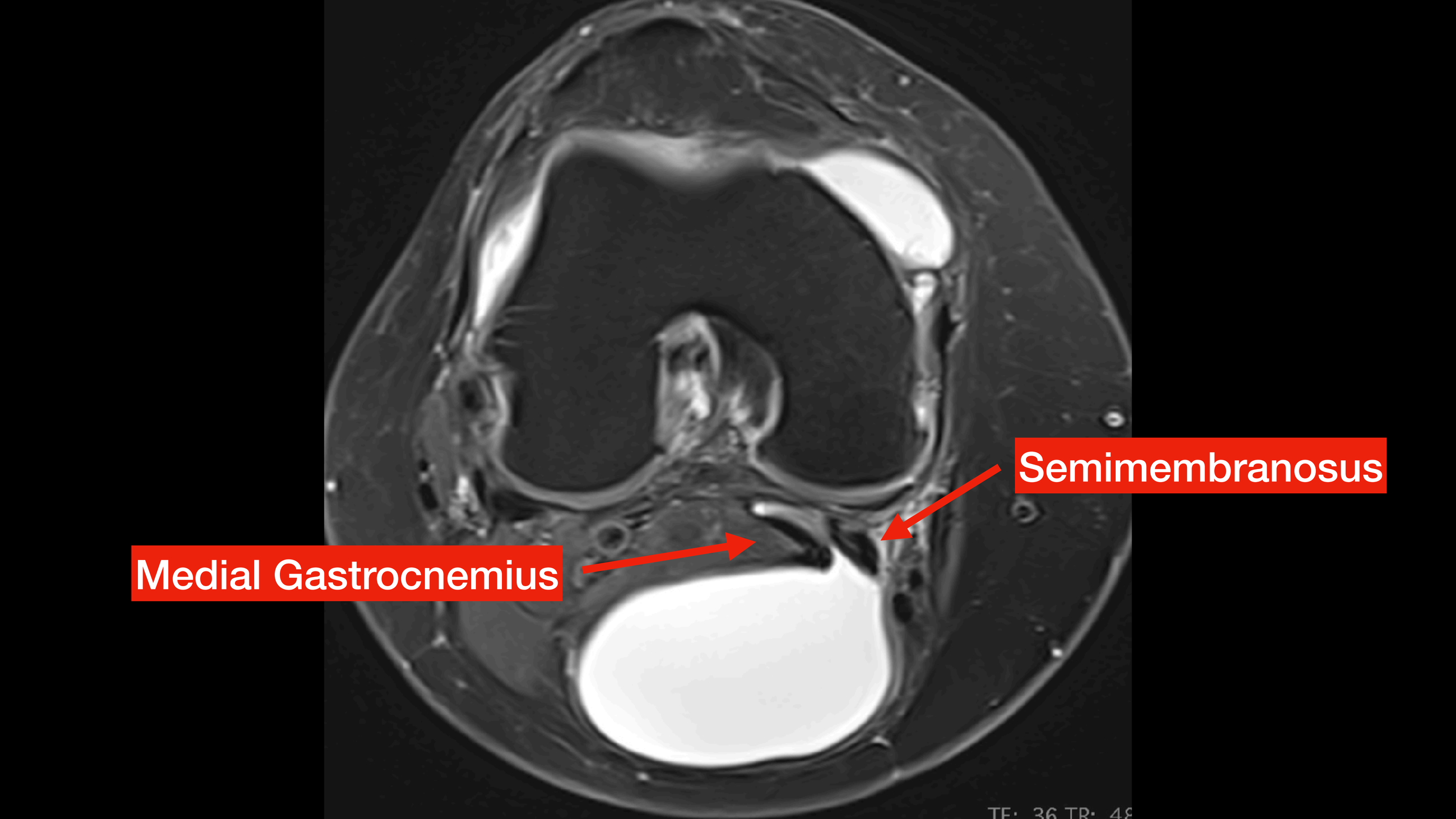
Semimembranosus
Medial Gastrocnemius

# Pathoanatomy

- Synovial fluid overproduction increases intra-articular pressure.
- 1-way valve mechanism prevents fluid return, leading to cyst formation.

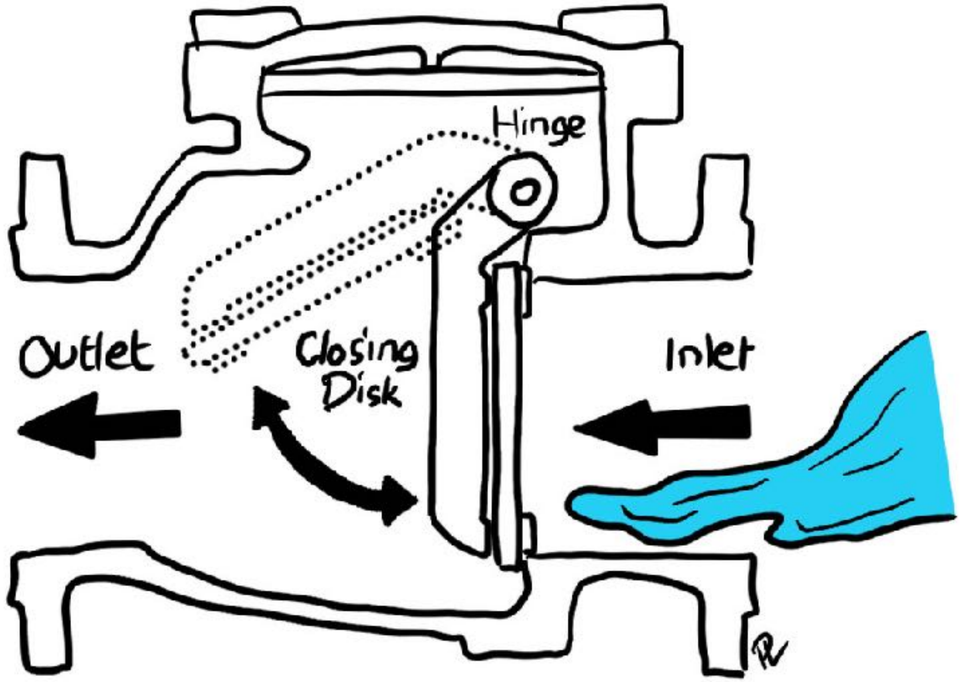


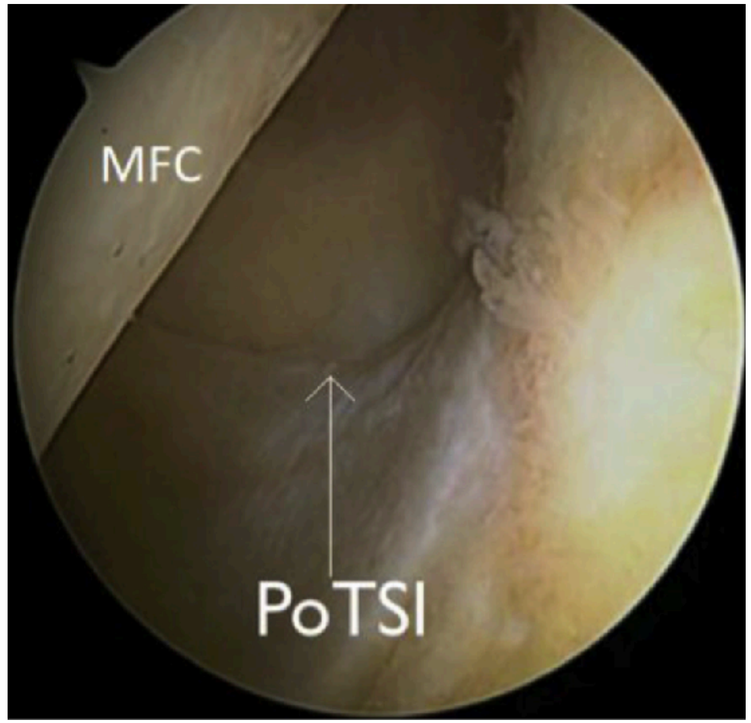


Brazier et al.

Posterior transverse synovial infold

# Pathoanatomy

- "Oblique popliteal ligament"

Contents lists available at ScienceDirect

Orthopaedics & Traumatology: Surgery & Research

journal homepage: www.sciencedirect.com/journal/orthopaedics-and-traumatology-surgery-and-research

Original article

## Arthroscopic evaluation of anatomical variations of the oblique popliteal ligament and their association with popliteal cyst formation

Fabio Carminati [a,b,*], François Kelberine [a]

[a] Pôle Aixois de Chirurgie Articulaire et Sportive, La Bastide d'Axium, 21, Avenue Alfred Capus, 13090 Aix en Provence, France
[b] Service de Chirurgie Orthopédique, Traumatologique et Vertébrale, Hôpital Sainte-Musse, 54, Rue Henri Sainte Claire Deville, 83056 Toulon, France

| | | |
|---|---|---|
| 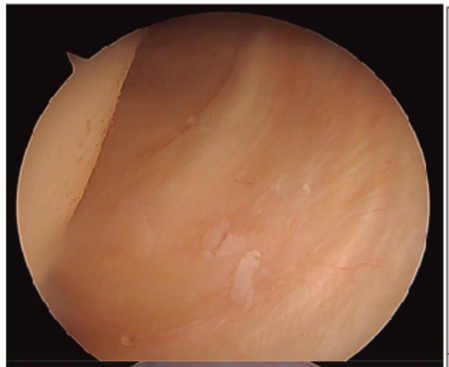 | TYPE 1 | Integrated into the capsule | Hook passage **impossible** behind the OPL |
| 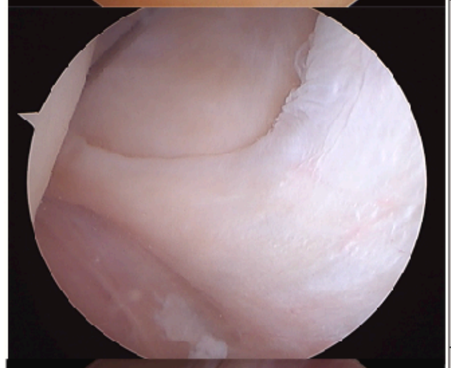 | TYPE 2A | Protruding into the joint = **Cord-Like** appearance | Hook passage **impossible** behind the OPL |
| 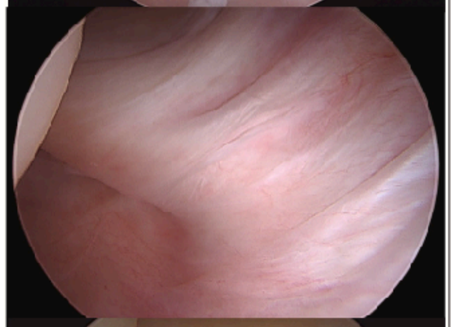 | TYPE 2B | Protruding into the joint, **normal** aspect | Hook passage **impossible** behind the OPL |
| 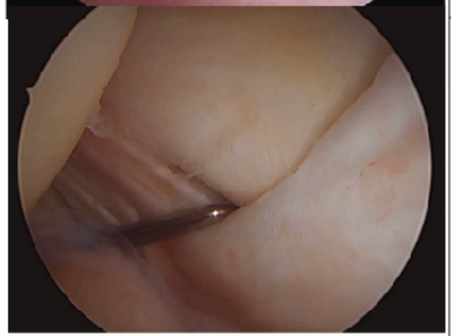 | TYPE 3 | Bulging into the joint with capsular fold +/- posterior communication toward a cyst | Hook passage **possible** behind the OPL |

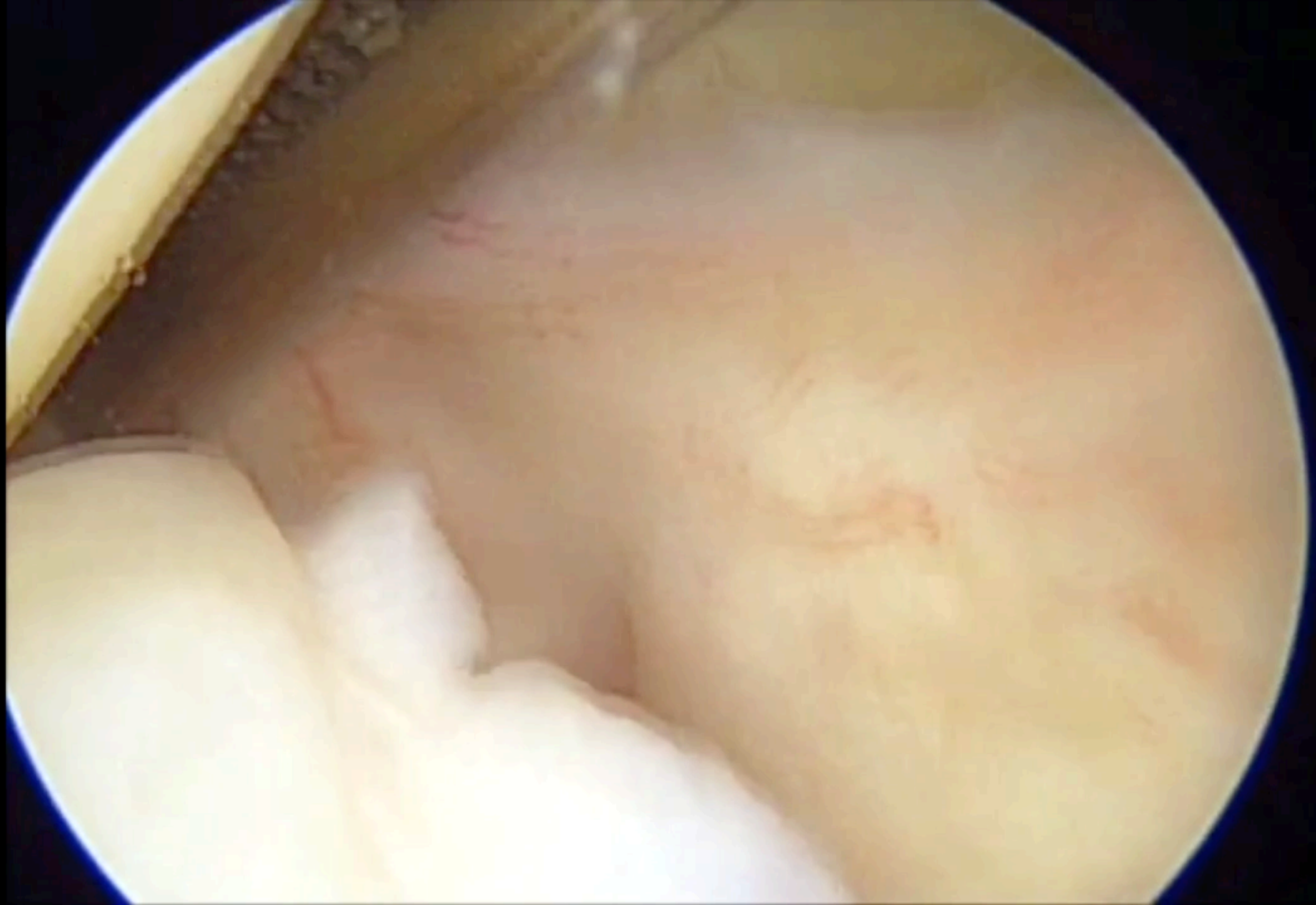

# Clinical Overview

- **Associated with intra-articular pathologies** (e.g., osteoarthritis, rheumatoid arthritis, meniscal tears). Osteocartilaginous loose bodies may be found within the cyst.
- Baker's cysts can be a source of **posterior knee pain** that persists despite surgical treatment of the intra-articular lesion.
- Chronic cysts **may cause complications** like rupture or neurovascular compression.




Baker's Cyst: Diagnostic and Surgical Considerations. T. J. Frush, and F. R. Noyes. Sports Health 2015

# Clinical Presentation: Key Symptoms

- Asymptomatic in some (or many) cases.
- Posterior knee pain and stiffness.
- Swelling in the popliteal fossa.
- Complications: Pseudo-thrombophlebitis (cyst rupture mimicking DVT).



# Clinical Presentation: Examination Findings

- Palpable, non-pulsatile mass in the popliteal fossa.
- Restricted range of motion due to cyst size.
- **Foucher's sign**: Mass becomes less apparent with knee flexion.



# Treatment Overview

- **1. Conservative management.**
- **2. Aspiration and injection.**
- 3. Surgical approaches: Arthroscopy and open excision.

# Conservative Management

- **Physical therapy** to improve joint mobility.
- **NSAIDs** for pain and inflammation.
- **Activity modification** to reduce stress on the knee joint.

# Aspiration and Injection

- **Aspiration** provides temporary relief but high recurrence rates (>50%).
- **Corticosteroid injections** reduce inflammation but do not address the underlying cause.

# Surgical Treatment: Arthroscopy

- **Treats underlying intra-articular pathology** (e.g., meniscal tears).
- Indirectly resolves cyst by reducing synovial fluid production.
- Recurrence rates: 30–40%.

# Open Excision?

- Rarely performed due to higher morbidity.
- Recurrence rates up to 50% if underlying pathology is not addressed.
- Reserved for very large or symptomatic cysts.

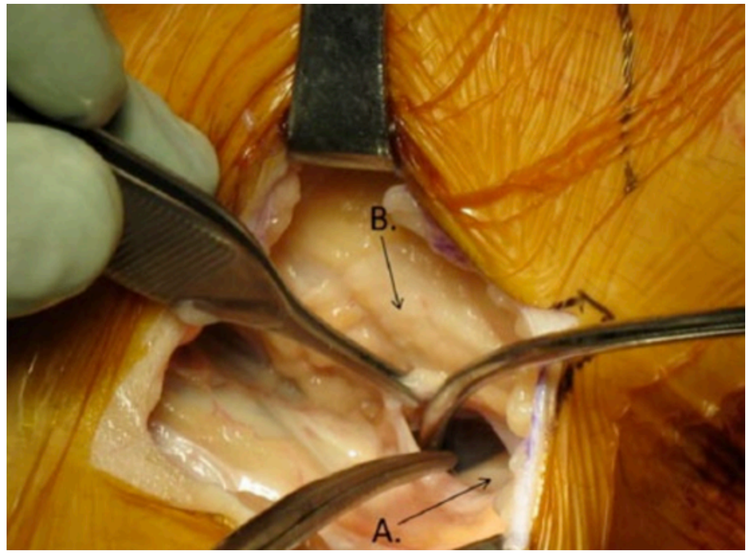


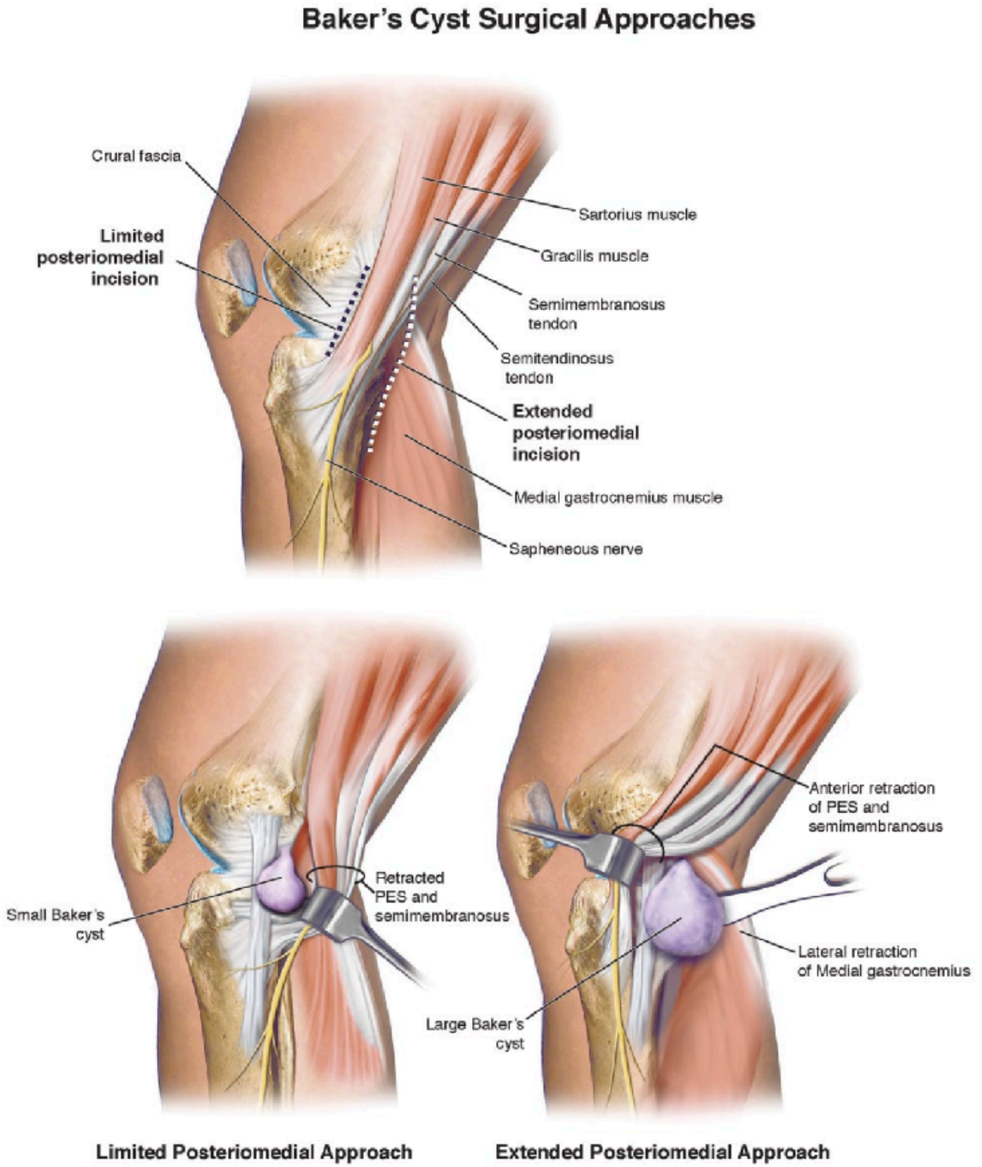


Baker's Cyst: Diagnostic and Surgical Considerations. T. J. Frush, and F. R. Noyes. Sports Health 2015

# Arthroscopy with Valve Excision

- **Valve excision** directly addresses cyst formation.
- Significantly lowers recurrence rates to 10–15%.
- Combined with treatment of the intra-articular lesion.

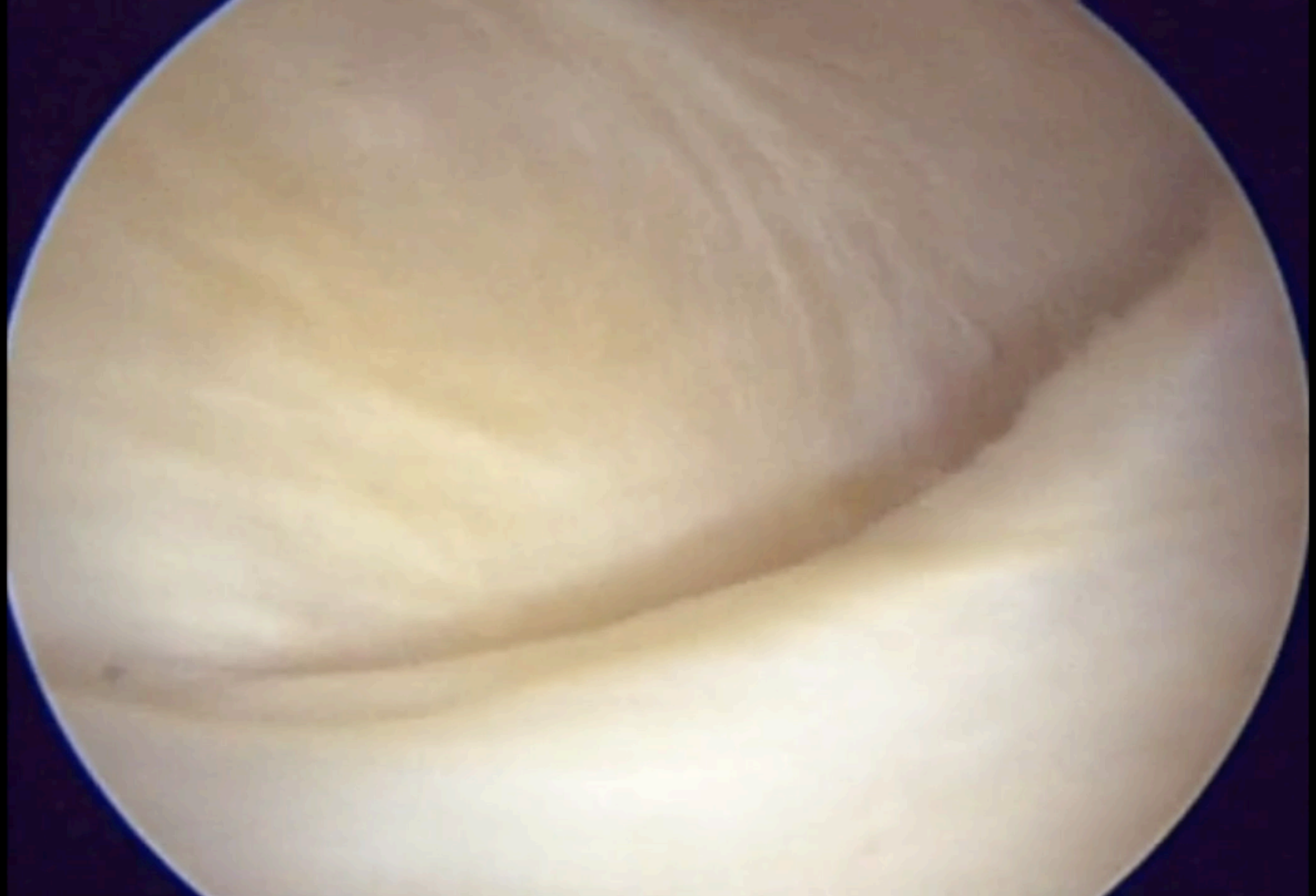

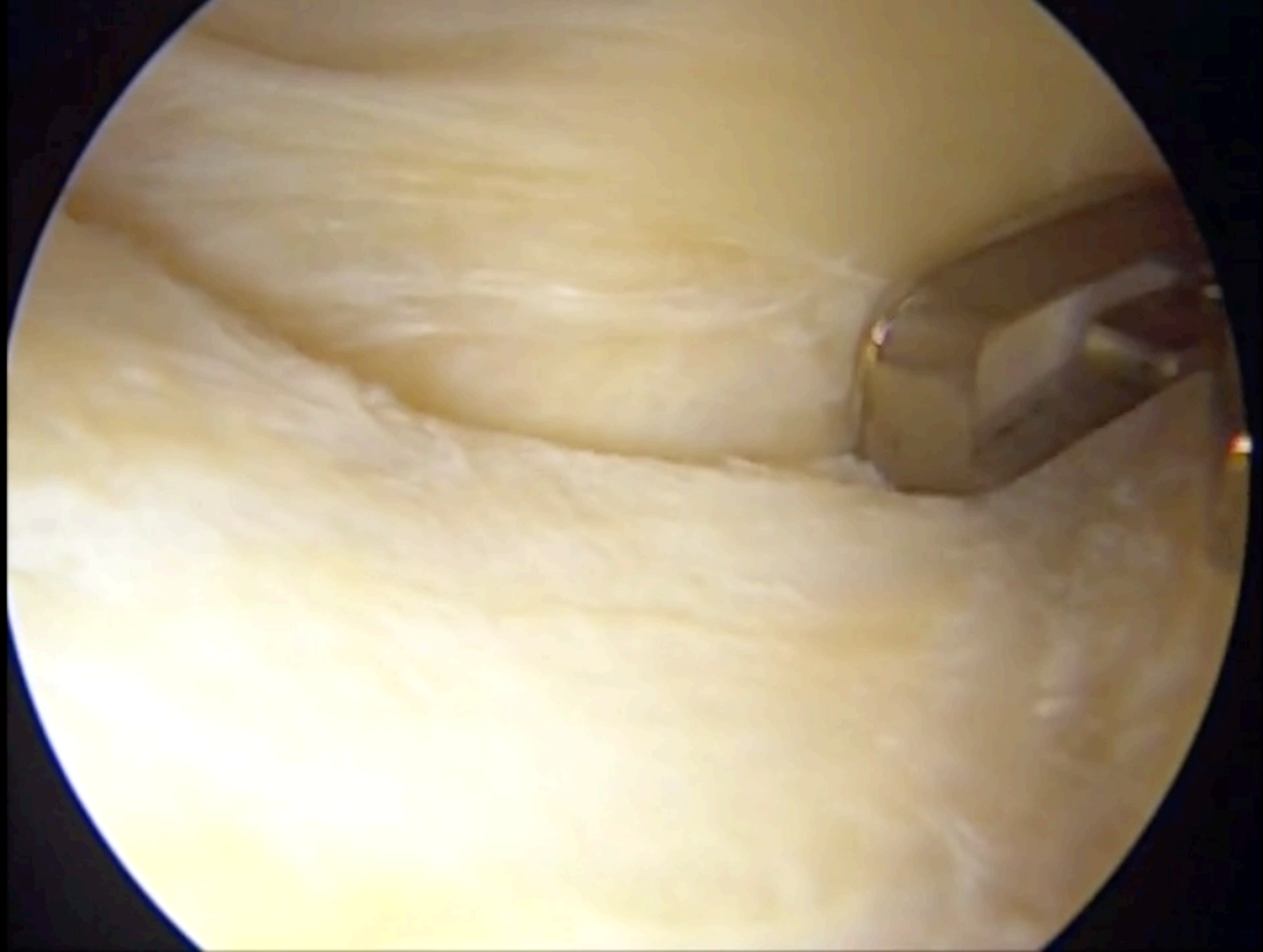

# Arthroscopy with Valve +/- Wall Resection

- Valve excision +/- cyst wall resection.
- Potentially beneficial for large or chronic cysts.
- Increased operative time and risks; recurrence ~5–10%.

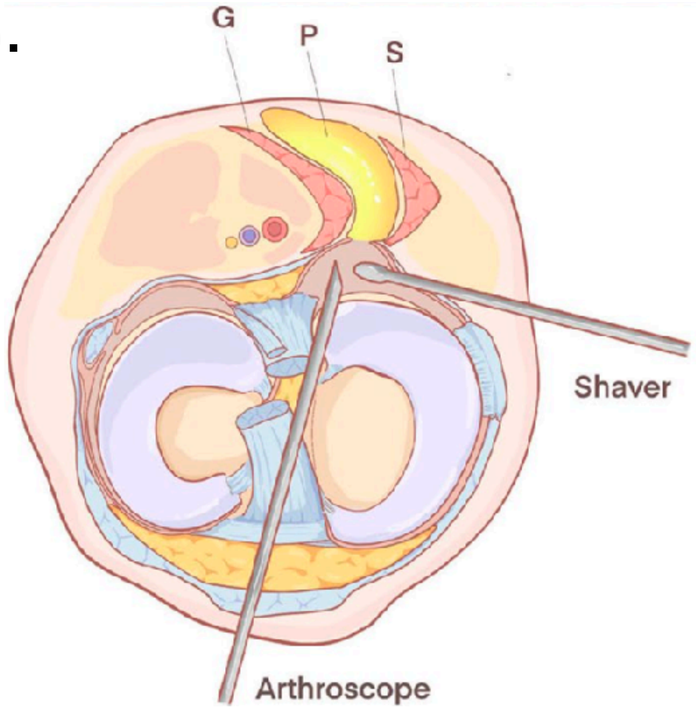


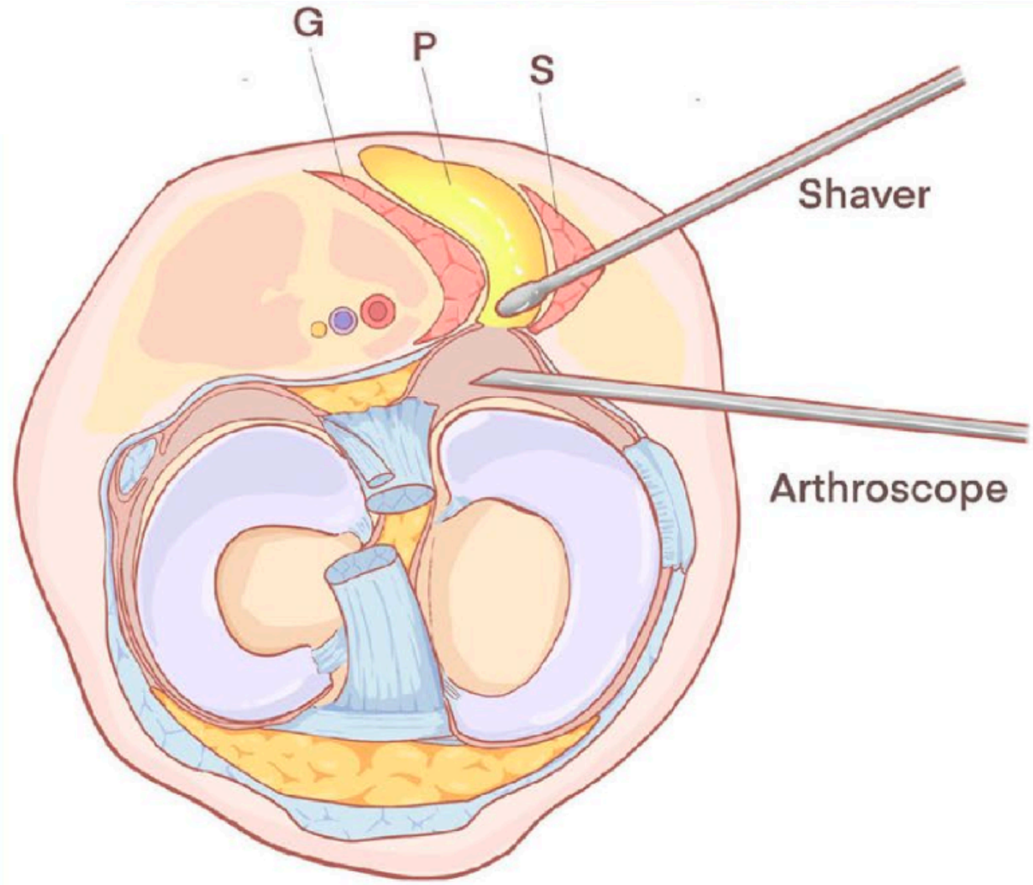


Ma et al. Double posteromedial portals versus single posteromedial portal for arthroscopic management of popliteal cysts. Journal of Orthopaedic Surgery and Research 2023

# Cyst wall resection or not?

Thamrongskulsiri et al. Systematic review and meta-analysis of studies comparing cyst wall preservation against cyst wall resection during arthroscopic popliteal cyst decompression. Archives of Orthopaedic and Trauma Surgery. 2024

- Systematic review
- Four articles included a collective of 214 knees. Level 3 evidence.
- Cyst wall resection: **MRI improvement and lower recurrence rate**.
- Cyst wall resection: **Higher complications**.
- **But Similar clinical outcomes.**

**Consensus on better MRI and less recurrence if wall resection**
**Consensus on more complications if wall resection**
**Controverse about effect on clinical outcomes**

Zhou et al. Surgical treatment of popliteal cyst: a systematic review and meta-analysis. Journal of Orthopaedic Surgery and Research. 2016

Li et al. Comparison of clinical outcomes associated with arthroscopic cyst wall preservation or resection in the treatment of popliteal cyst: a systematic review and meta-analysis. Archives of Orthopaedic and Trauma Surgery. 2021

# Comparison of Treatments

- Simple arthroscopy: Low risk, recurrence ~30–40%.
- Arthroscopy + valve excision: Recurrence ~10–15%.
- Arthroscopy + valve + wall resection: Lowest recurrence (~5–10%).

# Conclusion

- Management of symptomatic popliteal cysts is first of all **conservative**.
- Intracystic aspiration and corticosteroid injection and possible cyst fenestration
- **Operative management** should be reserved for persistently symptomatic cysts

# Conclusion

- Surgical treatment must include addressing the **primary intra-articular pathology** in addition to the cyst itself
- If surgical excision becomes necessary:
  - **Arthroscopy with valve excision** is the most effective option
  - **Cyst wall resection** has less recurrence.
  - Similar clinical outcomes with or without wall resection?

# Thank you

