Clinical case

A.A.

Philippe Landreau, MD
Consultant Orthopaedic Surgeon
Dubai
UAE

Clinical presentation

- 60 yo
- Operated stomach neoplasm one year ago. Recent PET scan: normal
- History of **right Baker cyst operated 2 times** (within one year), open procedures with recurrence. **3 aspirations** and steroid injections: no improvement.
- Recent **worsening of the pain, redness and possible fever**.

Clinical presentation

- Voluminous cyst, some local inflammation.
- Tenderness on the cyst area and all popliteus and proximal posterior calf area.



MRI



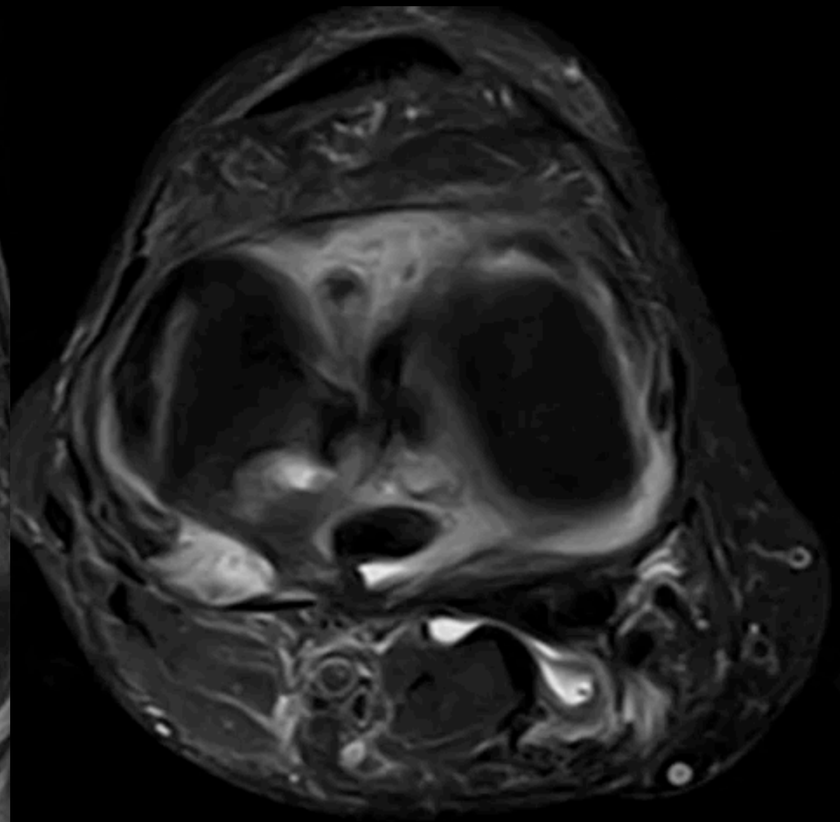



What do you do? What additional investigations or treatments do you recommend?



Infection? DVT?

- Doppler: no deep veinous thrombosis on right lower limb.
- WBC count: 6090. CRP: 172.

What do you do? What additional investigations or treatments do you recommend?

Infection?

- Aspiration from the cyst: Only 50 ml bloody fluid. No sign of infected.
- Bacteriology: negative

What do you do? What additional investigations or treatments do you recommend?

Surgery

- Plan:
- Right knee arthroscopy for exploration and treatment + samples for bacteriology.





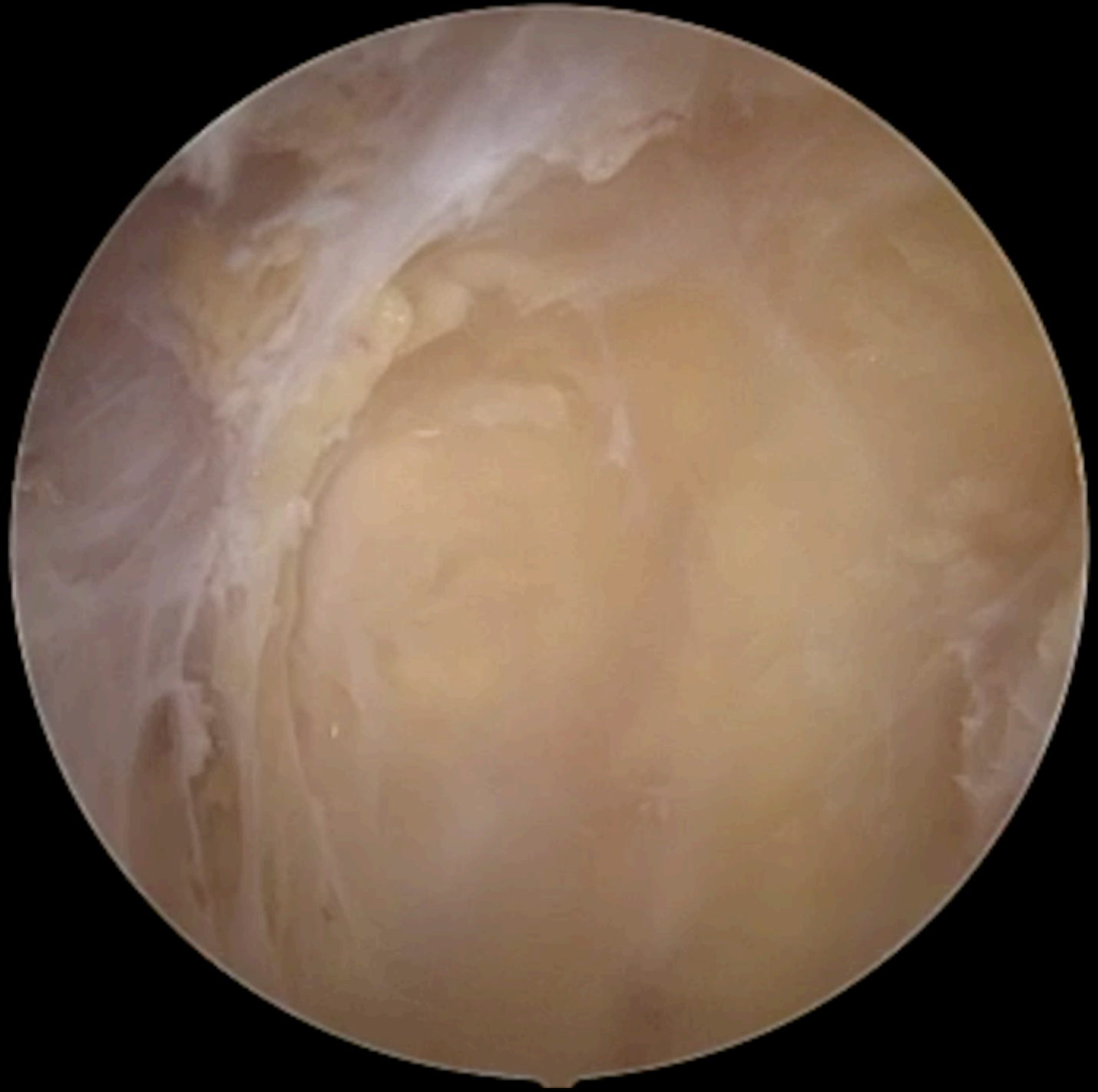



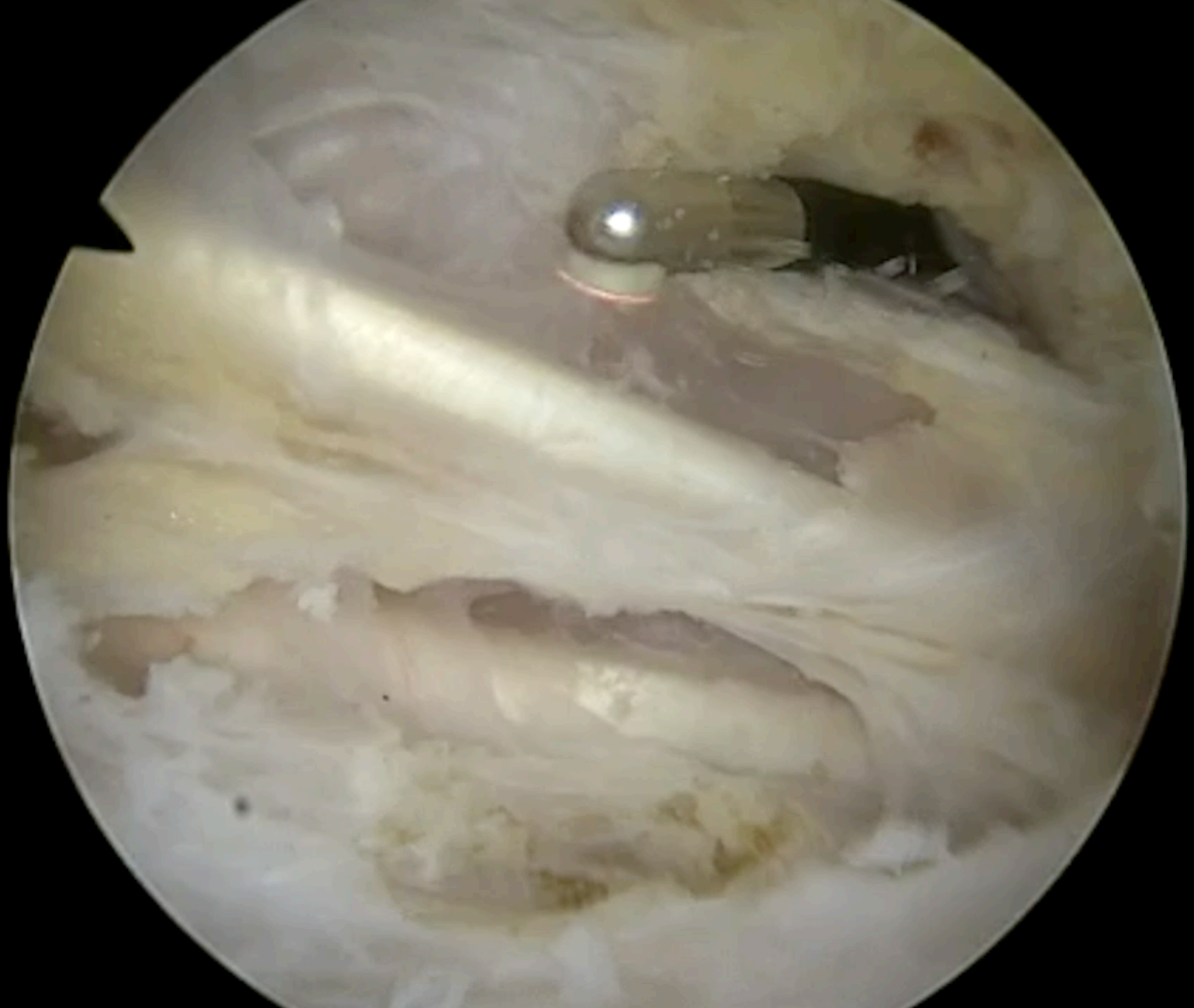

Outcomes 4 years.

- (Bacteriology negative)
- No recurrence
- No more posterior pain
- Perfect recovery excepts some knee symptoms consequence of the osteoarthritis.

Lesson from this case

- Valve

